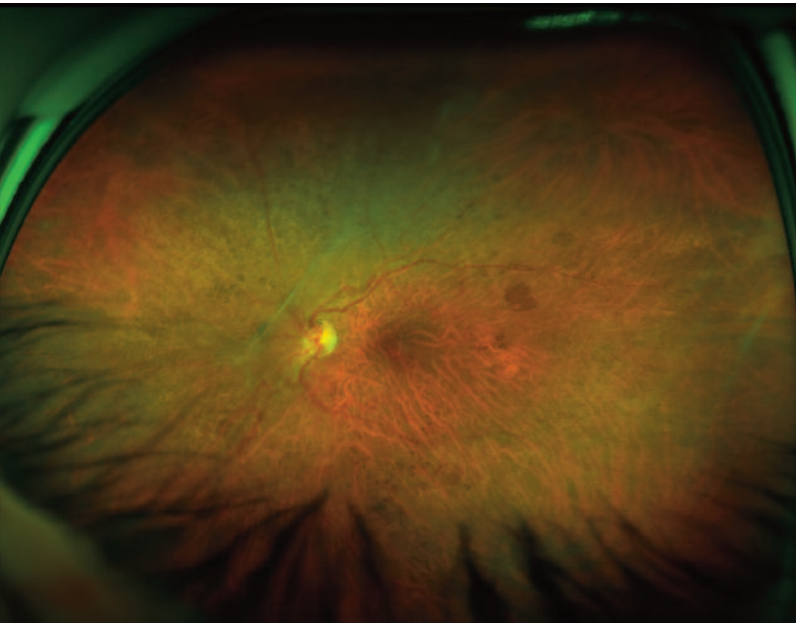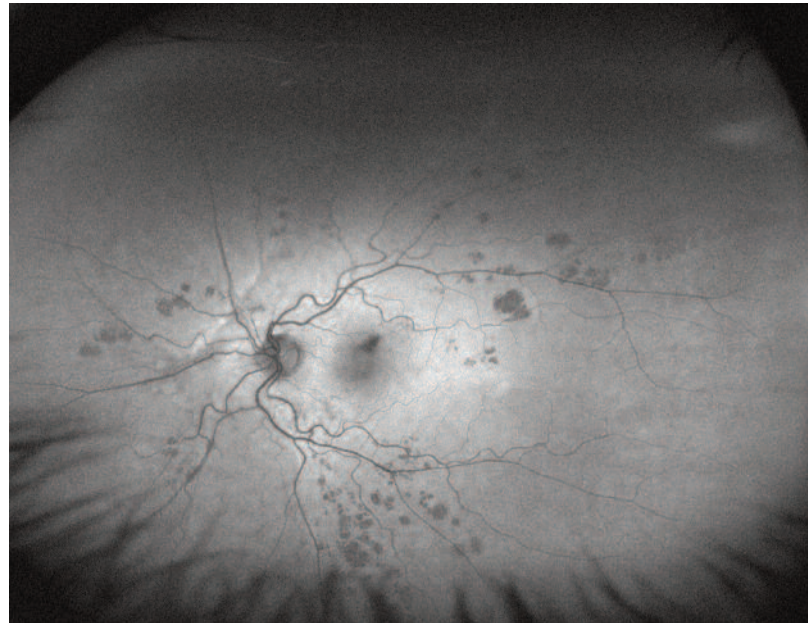


optomap image – Patient left eye – Bear Tracks Evident



optomap *af* images – Patient left eye – Bear Tracks Confirmed

In April of 2015 Mary visited her optometrist at Karns Vision Center in Knoxville, TN complaining of vision loss. Mary also let her doctor know that she was currently battling lung cancer in the event that her diagnosis and treatment were affecting her vision. The doctors at Karns Vision Center include **optomap** retinal imaging as part of their comprehensive eye exam for all of patients.

The doctor also included an autofluorescence **optomap** (**optomap *af***) to determine if there was anything happening in the RPE. In Mary's case there were significant bear tracks in her periphery and macula, as confirmed by the **optomap *af*** image, above which were causing her vision problems.

The evidence of bear tracks in the retina has also been linked with an increased chance of developing colon cancer. Based on the images above, Mary was advised to seek additional medical care to determine her treatment of care.

*Even in unfortunate situations such as Mary's, **optomap** is providing us with the ability to discover and treat our patients earlier and more effectively. **optomap** assists us in discovering pathologies that may have gone unnoticed using traditional imaging techniques.*

Drs. Shane and Michelle Presson
Karns Vision Center

Optos plc
Tel: +44 (0)1383 843300
info@optos.com

Optos, Inc
Call Toll-free (US & Canada):
800-854-3039
Outside of the US: +1 508 787 1400
usinfo@optos.com

Optos Australia
Tel: +61 8 8443 4533
auinfo@optos.com



Building *The* Retina Company

