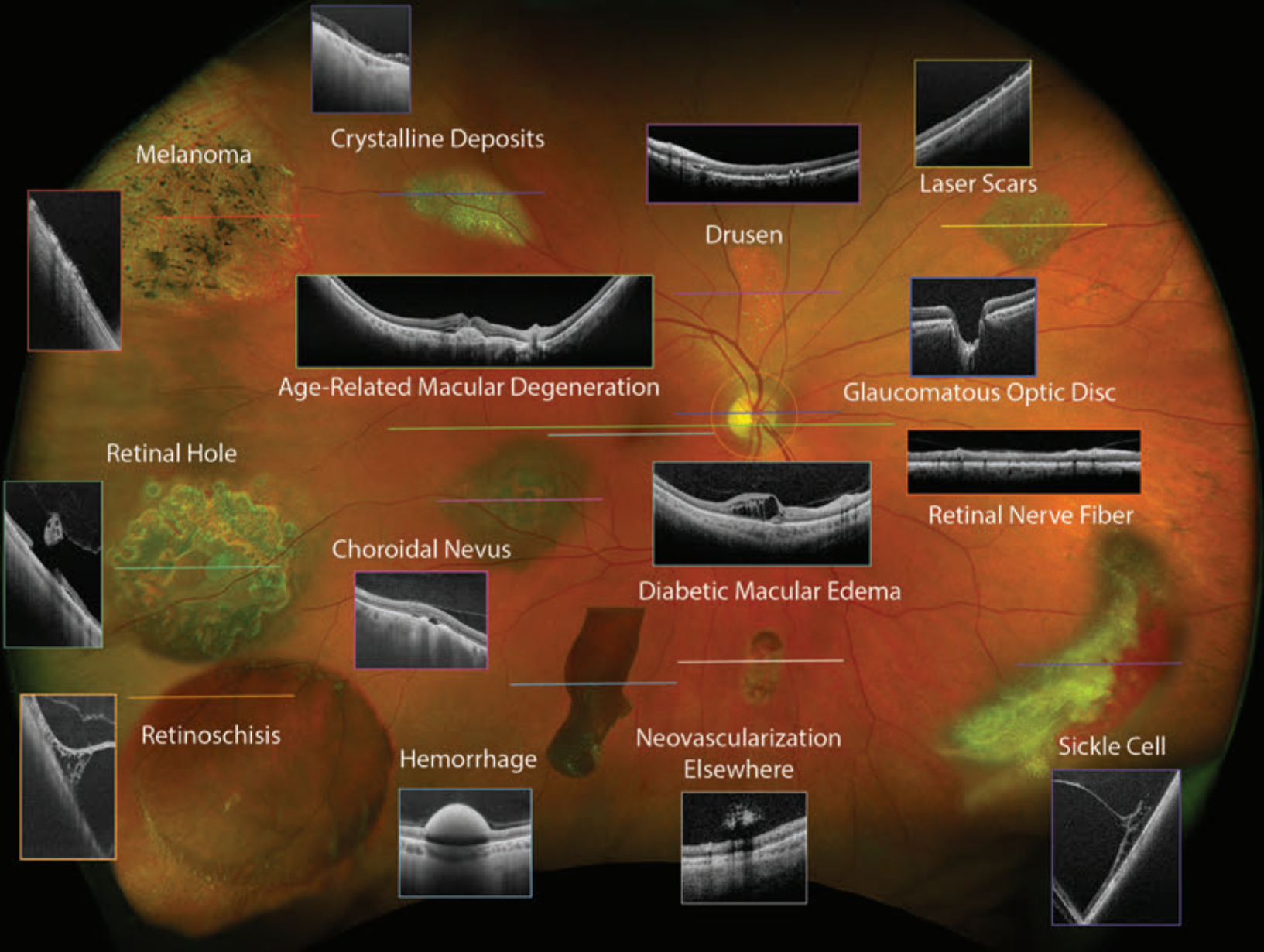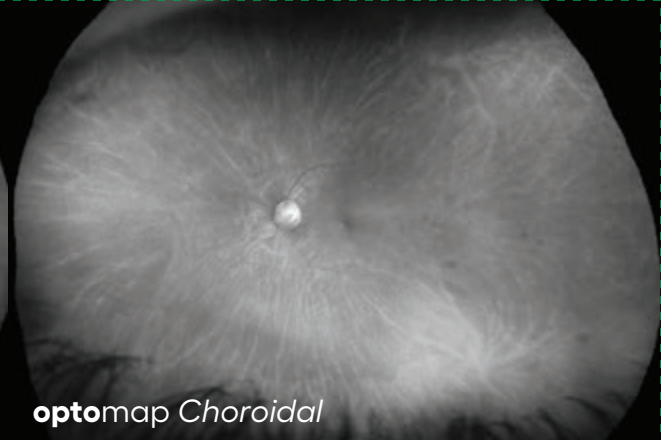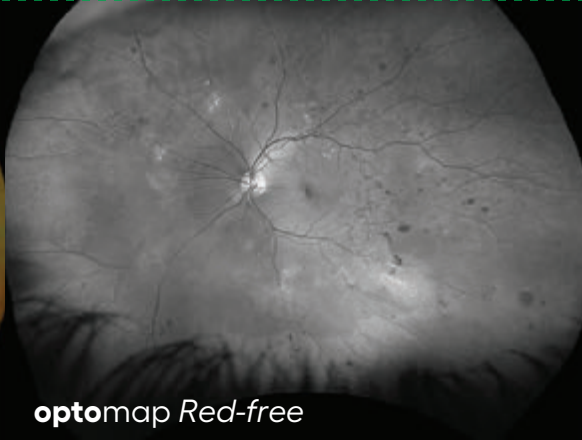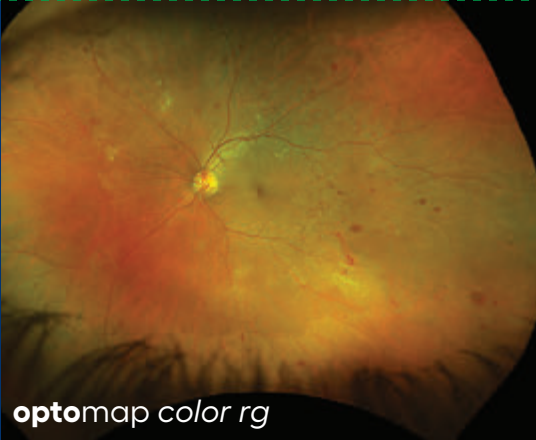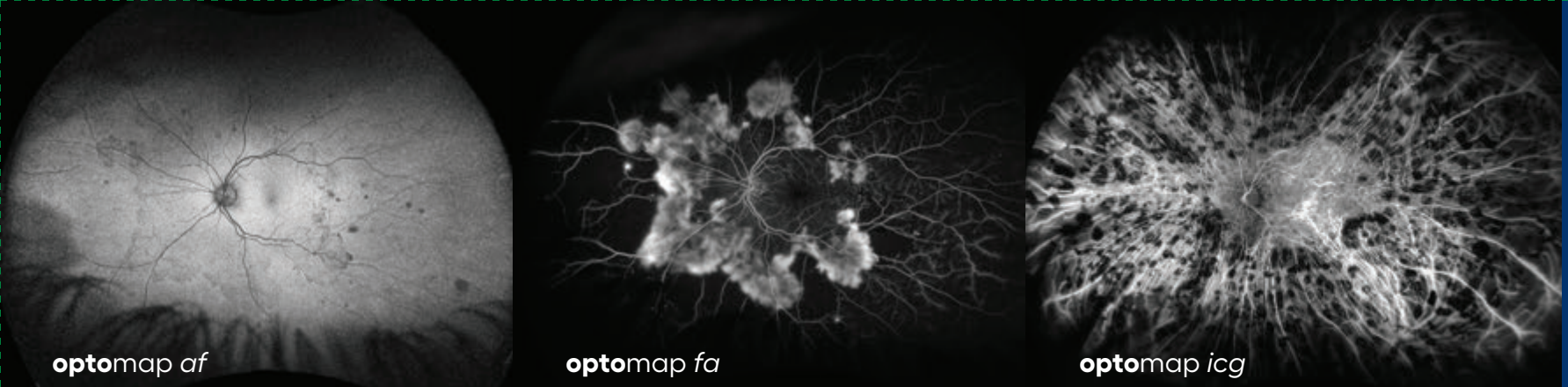


Optos devices produce ultra-widefield (UWF™), high resolution digital images (**optomap**®) of approximately 82% (200°) of the retina in less than ½ a second, documenting from the macula and beyond the vortex ampullae, something no other device is capable of capturing in a single image.

optomap color rg images provide clinical information which facilitates the early detection, management and effective treatment of retinal and systemic diseases.

These images consist of two channels of information, a red channel (635nm) which visualizes the choroidal layer and a green channel (532nm) which visualizes the retinal pigment epithelium (RPE).

optomap af images are captured using the green wavelength (532nm) and visualize the function of the RPE.

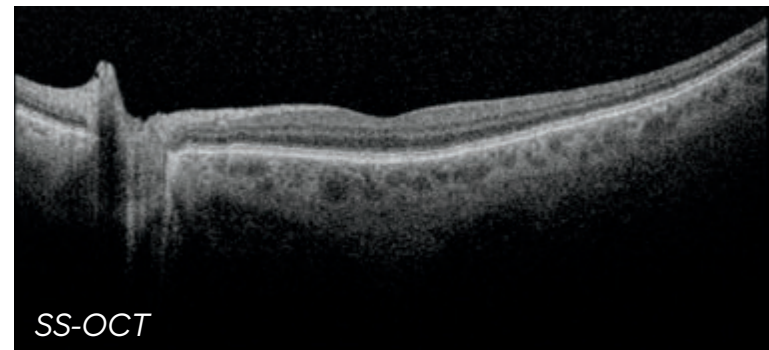


optomap *fa* images are captured using the blue wavelength (488nm) to visualize the circulation of the retina vasculature. This modality is an option on the *Silverstone* device.

optomap *icg* images captured using the infrared wavelength (802nm) to visualize the circulation of the choroidal vasculature. This modality is an option on the *Silverstone* device.

optomap is used for planning OCT scans which provide cross sectional views of the retina registered to the **optomap** where nearly all retinal layers can be visualized.

Optos provides two types of OCT technology: an *SD-OCT* for imaging the central pole in the *Monaco* device and an *SS-OCT* for imaging both the central pole and the peripheral retina, able to capture a scan anywhere within the **optomap** field of view in the *Silverstone* device.



Retina is the light-sensitive layer of tissue that lines the inside of the eye and sends visual information through the optic nerve to the brain

Choroid is the vascular (major blood vessel) layer of the eye lying between the retina and the sclera. It provides nourishment to outer layers of the retina

Vein is any of the tubes forming part of the blood circulation system of the body, carrying in most cases oxygen-depleted blood toward the heart

Artery is a blood vessel forming part of the circulation system by which blood (mainly that which has been oxygenated) is conveyed from the heart to all parts of the body

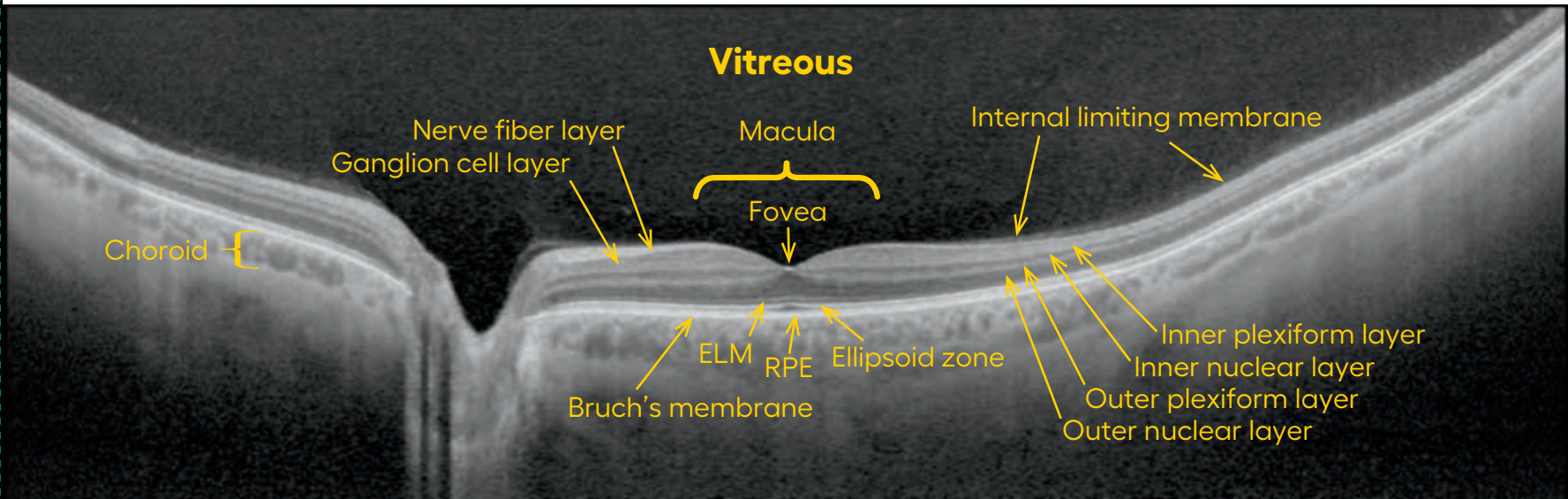
Macula is a small central area of the retina surrounding the fovea; area of acute central vision

Optic Nerve Head (ONH) is the ocular end of the optic nerve. Denotes exit of retinal nerve fibers from the eye and entrance of blood vessels to the eye

Fovea is the central pit in the macula that produces the sharpest and most detailed vision. It contains a high concentration of cones and no retinal blood vessels

Vortex Veins are large veins that mark the anatomical equator and where the choroidal veins drain. There is at least one vortex ampulla per quadrant but there may be more

Line-scan of a Healthy Retina



Vitreous – Clear ‘jelly’ like liquid that fills the eye from the lens to the ILM

Internal limiting membrane (ILM) – A thin membrane that covers the retinal surface in between the retina and vitreous

Macula – The area on the retina where central vision occurs. It is slightly pigmented and is around 5-6 mm in diameter

Fovea – located in the center of the macula and responsible for central vision. The normal fovea has a dip where the inner retinal layers are displaced causing a foveal ‘pit’ like depression

Nerve fiber layer (NFL) – a bright band on top of the retina that is made up of nerve fiber bundles which are axons of ganglion cells that carry the visual signal from the ganglion cell in the retina to the brain (forming the optic nerve)

Ganglion cell layer – dark band below the NFL made up of the ganglion cell bodies

Inner nuclear layer – dark band where bipolar cells and amacrine cells are located

Bruch’s membrane – thin layer separating the RPE from the choriocapillaris

Inner plexiform layer – bright band made up of ganglion cell dendrites where ganglion cells connect to bipolar cells and amacrine cells. Inner nuclear layer – dark band where bipolar, horizontal, and amacrine cell bodies are located

Outer plexiform layer – bright band where bipolar and horizontal cells connect to photoreceptors

Outer nuclear layer – dark band where photoreceptor cell bodies are located (rods and cones)

External limiting membrane (ELM) – thin layer near the bottom of the retina separating the photoreceptor inner and outer areas from their cell bodies

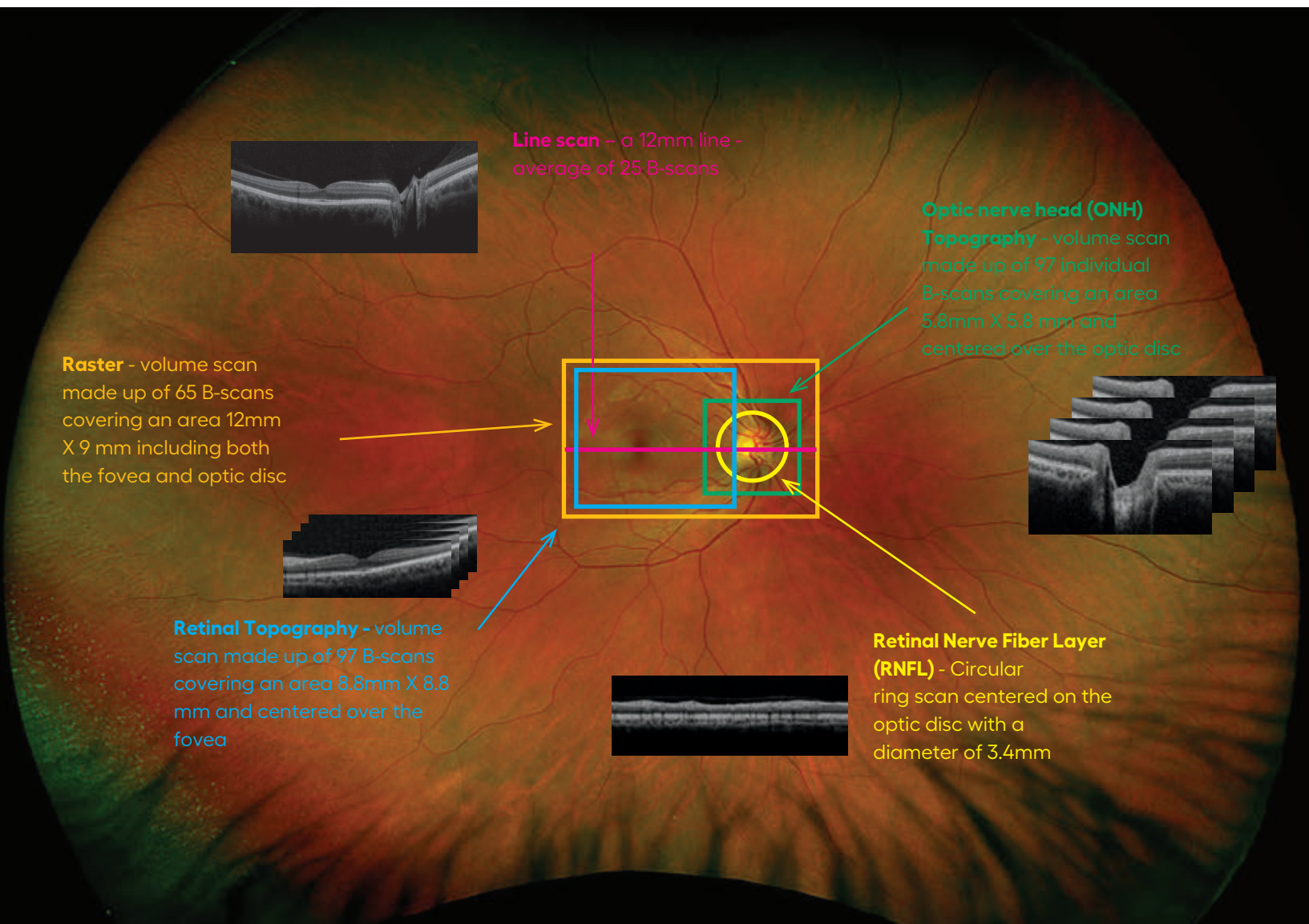
Ellipsoid zone – bright band that separates the inner and outer areas of photoreceptors (sometimes referred to as the IS/OS border)

Retinal pigment epithelium (RPE) – a thin pigmented layer that nourishes the photoreceptor layer

Choroid – the vascular layer of the eye containing blood vessels that nourish the outer retinal cells (photoreceptors, bipolar and horizontal cells)

Monaco OCT

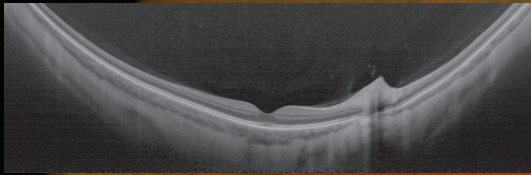
provides high-resolution cross-sectional SD-OCT images and volume scans can be captured through the fovea and optic nerve. Individual B scans range in length from 5.8 mm to 12 mm and volume scans range in size from 5.8 x 5.8 mm to 12 x 9 mm. *Monaco* scans at a speed of 70,000 kHz (A scans per second) and has a depth resolution of 7 microns optical and a digital resolution of 5 microns.



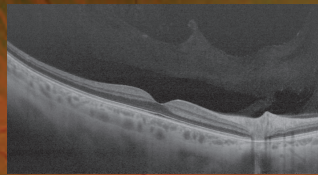
Silverstone **optomap**-guided OCT

provides high resolution cross sectional swept source OCT images and volume scans captured through the fovea and optic nerve as well as navigated anywhere on the **optomap**. Individual B scans range in length from 6 mm to 23 mm and volume scans range in size from 3.5 x 6 mm to 14 x 9 mm. *Silverstone* OCT scans at a speed of 100,000 kHz (A scans per second) and has a depth resolution of 7 microns optical and a digital resolution of 5 microns.

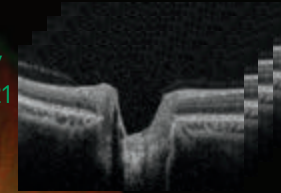
Extended line - a 23mm line – average of 15 B-scans



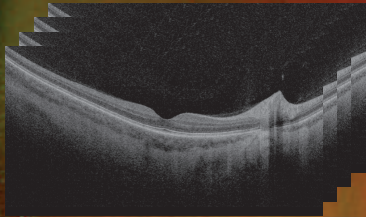
Line - a 14mm line – average of 25 B-scans




Optic nerve head (ONH) Topography - volume scan of 121 individual B-scans covering an area 6 mm X 6 mm and centered over the optic disc




Raster - volume scan - 121 B-scans covering an area 14mm X 9 mm including both the fovea and optic disc



Retinal Topography - volume scan - 121 B-scans covering an area 9 mm X 9 mm and centered over the fovea



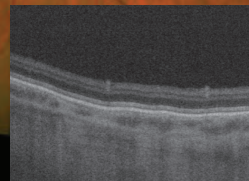
Navigated volume - 121 B-scans covering an area 6 mm X 6 mm



Navigated HD Volume - 121 individual B-scans covering an area 3.5 mm X 6 mm

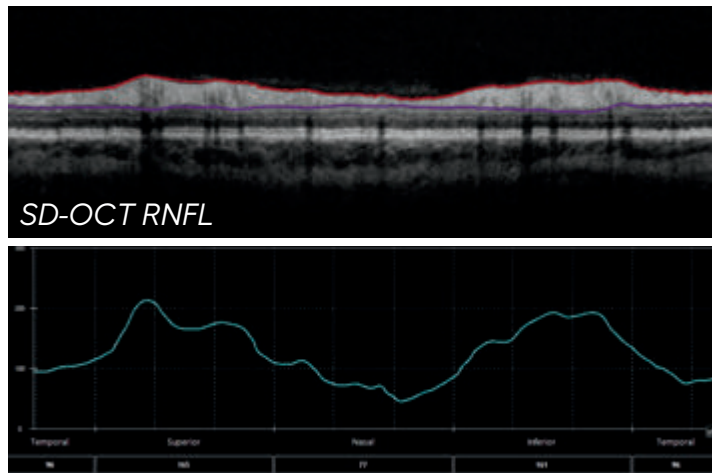
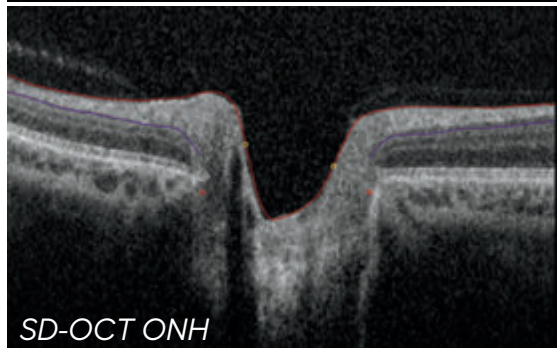
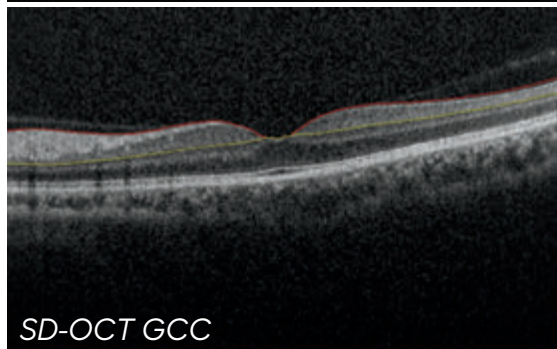
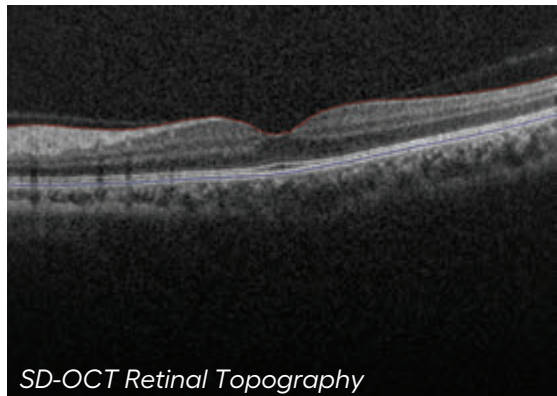


Navigated line - 6mm long line – average of 25 B-scans



Monaco Segmentation

includes software which automatically segments the retinal layers. This can help users identify areas of abnormality including: thickening or thinning of the retinal layers or the presence of fluid. This includes thickness maps as well as measurement parameters for full retina thickness, ganglion cell complex (GCC), retinal nerve fiber layer (RNFL) and optic nerve head (ONH).

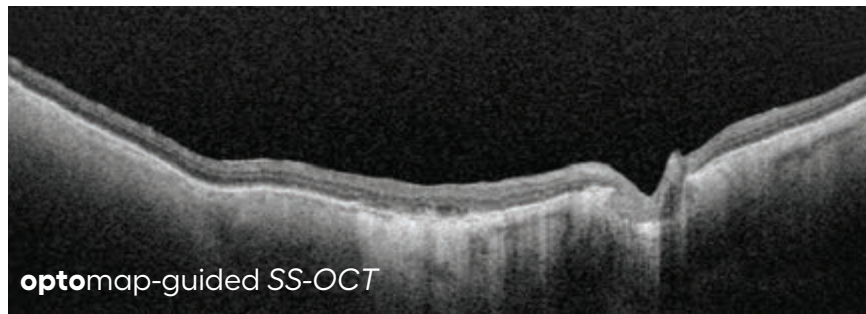
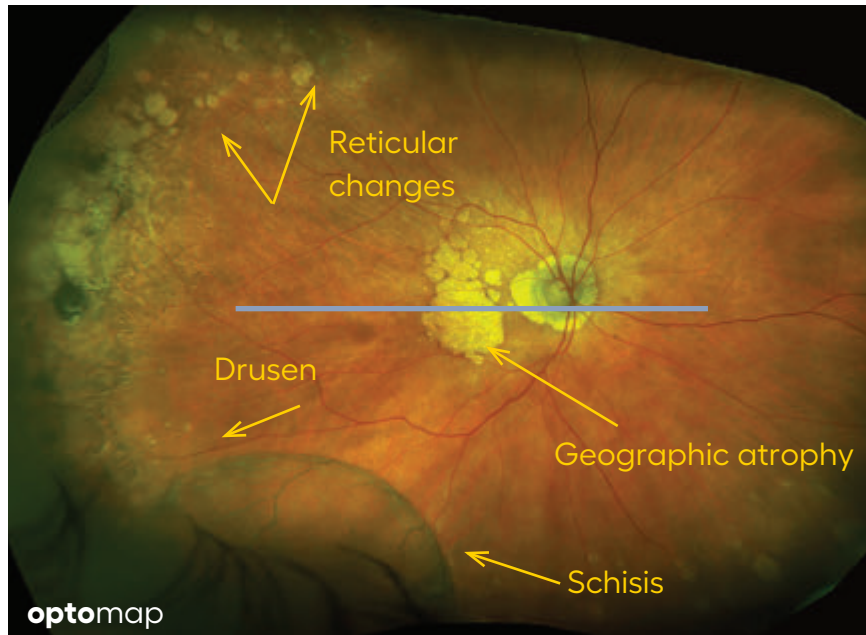


Monaco segmentation is also used to assess the RNFL and optic nerve head to help identify abnormalities.

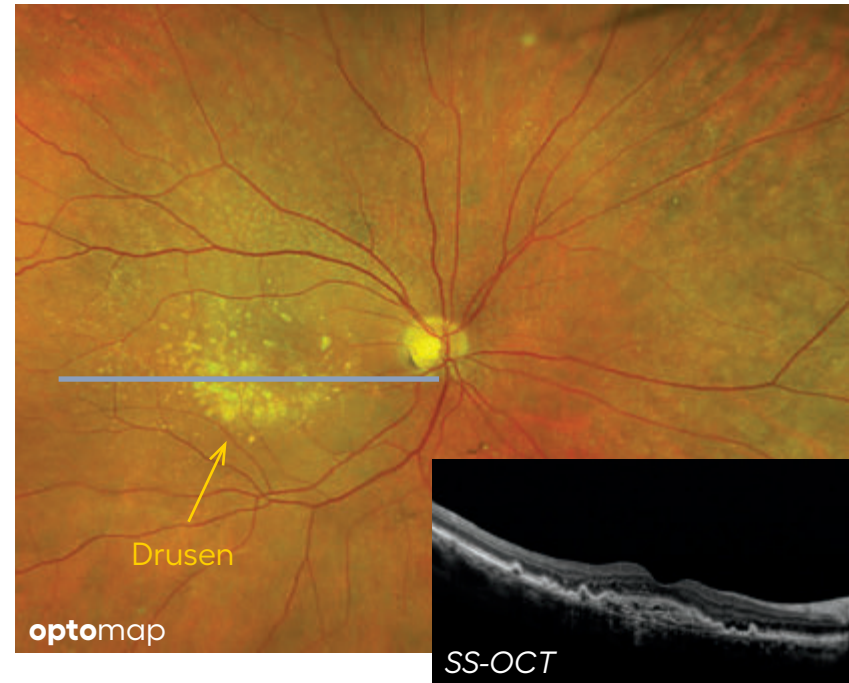
Age-Related Macular Degeneration (AMD)

is a common eye disease in older individuals that involves deterioration of the macula, resulting in loss of sharp central vision. Optos devices allow for multimodal assessment of this condition which impacts the retina and choroid.

Dry AMD is when geographic atrophy or drusen are present.

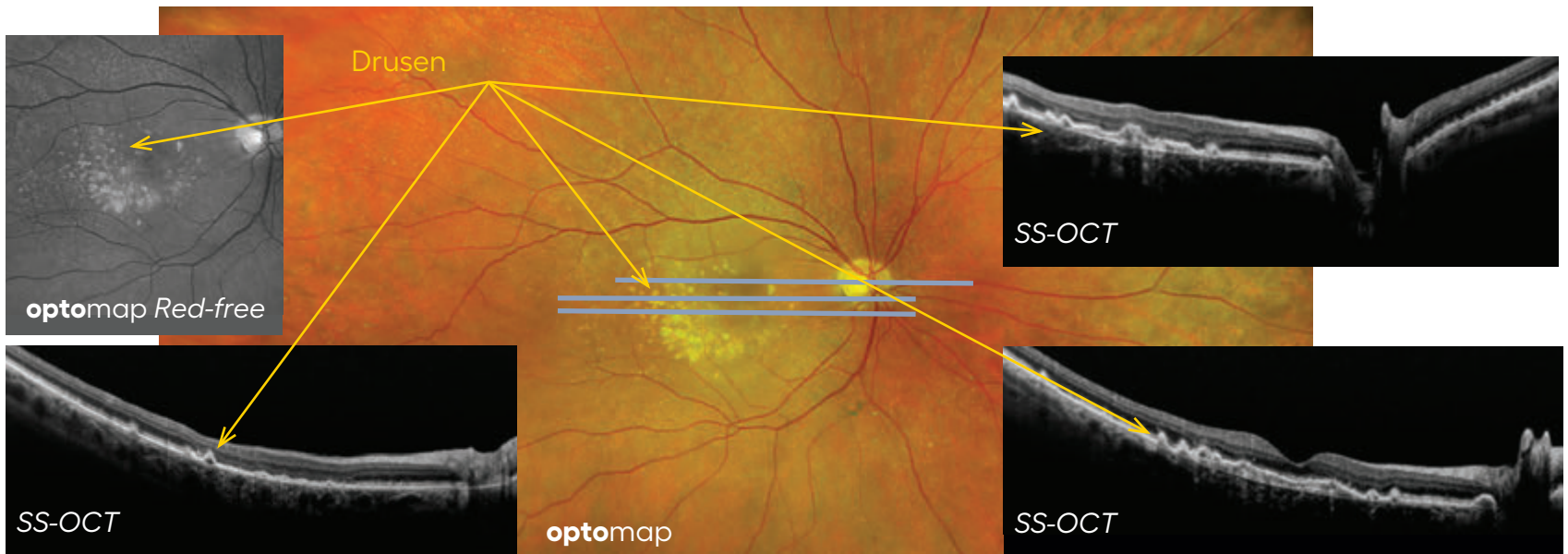
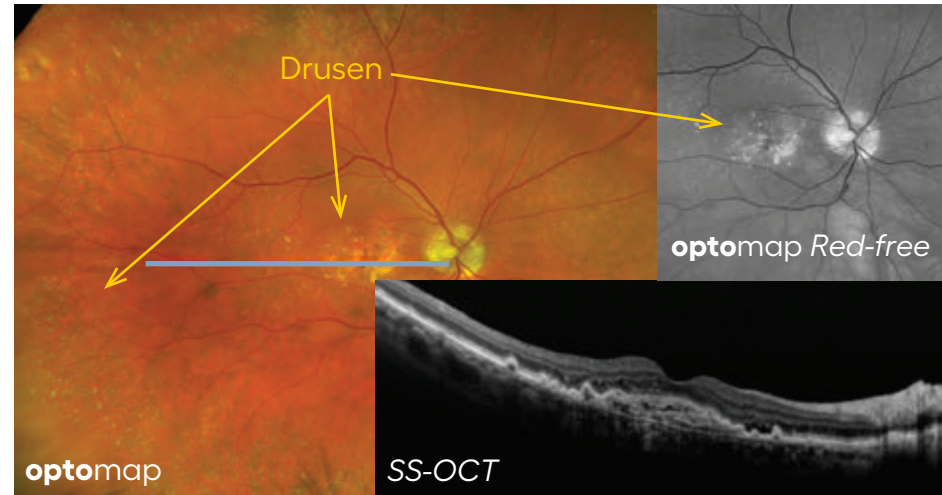
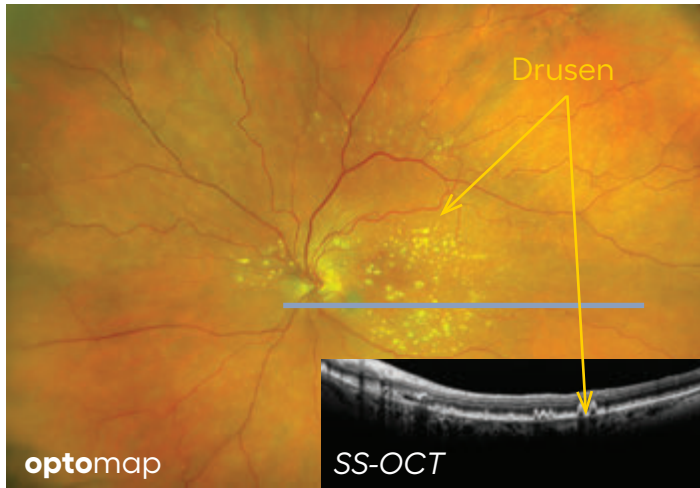


Geographic atrophy (GA) is a type of dry AMD where the RPE is atrophic. This causes the photoreceptors to also die resulting in vision loss. On the OCT GA shows up as hyperreflective 'column' below the RPE layer. Retinal atrophy anterior to the GA is also present. **optomap af** can be used to assess the progression of the disease.



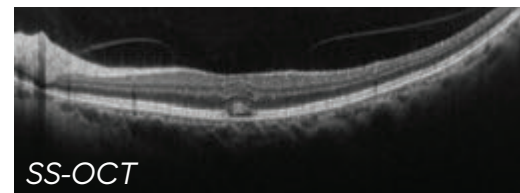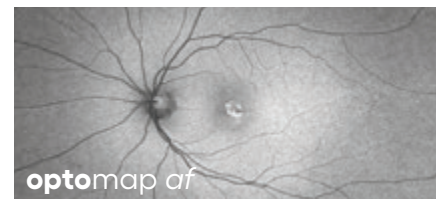
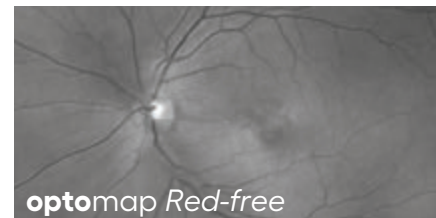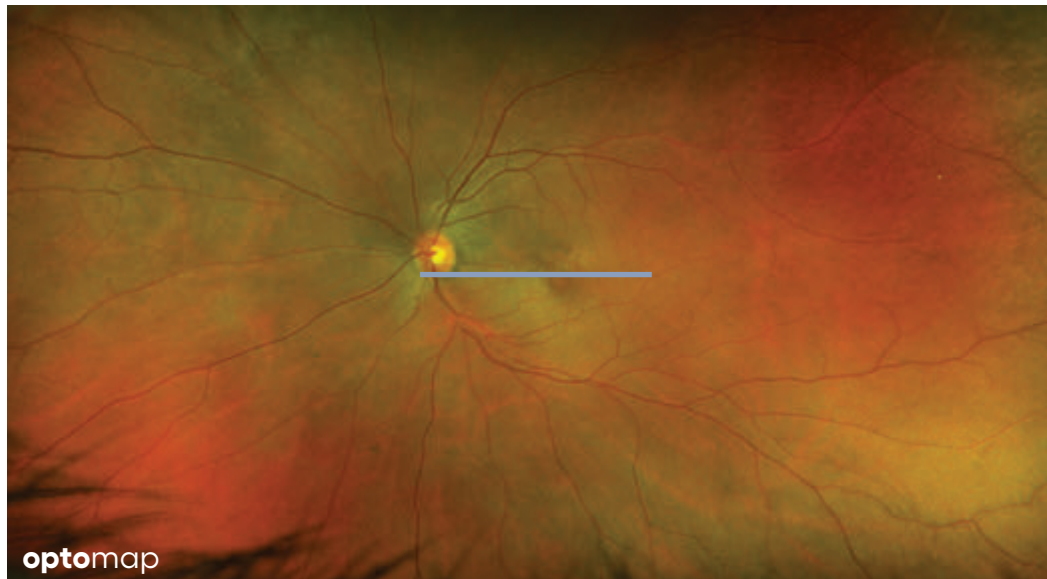
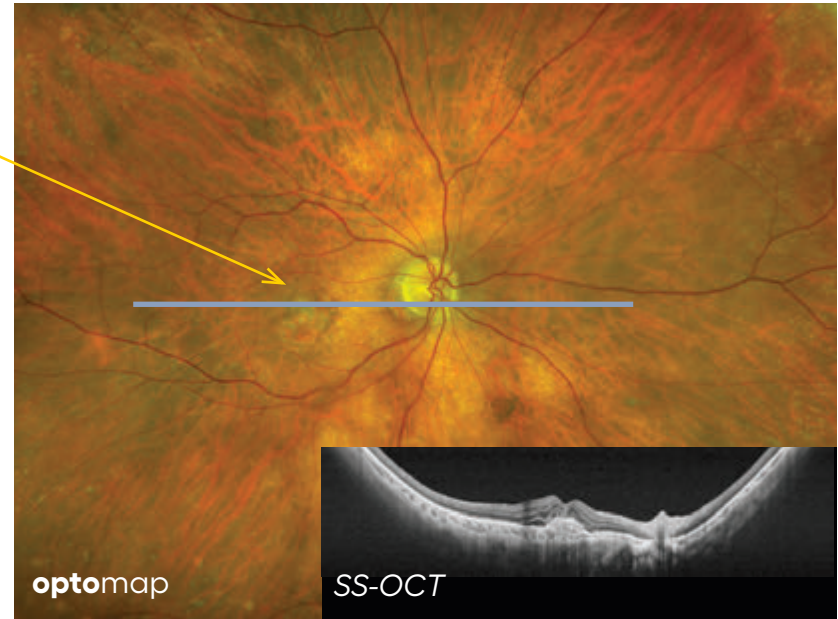
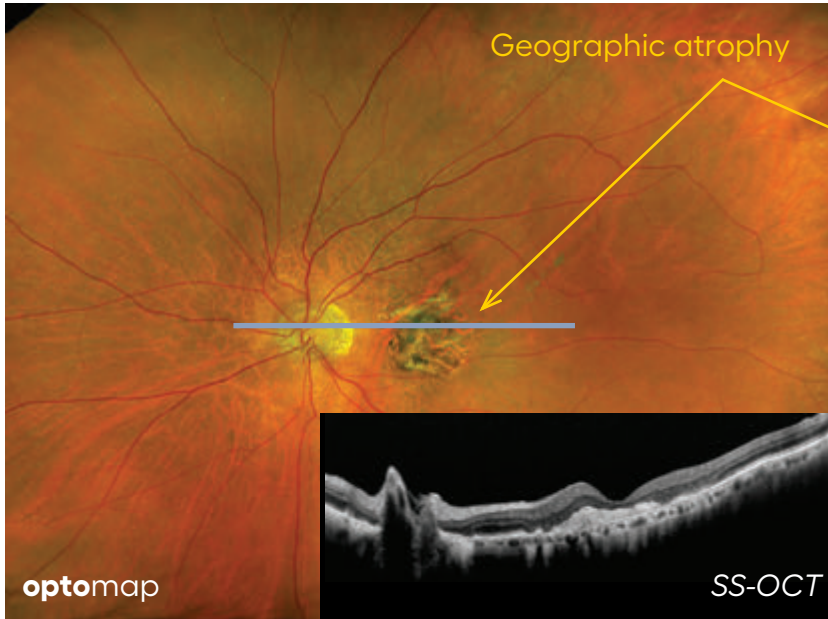
Drusen

are a feature of AMD, they are small lipid deposits on Bruch's membrane or RPE. They appear as yellow spots on the **optomap** image and white bumps on OCT.



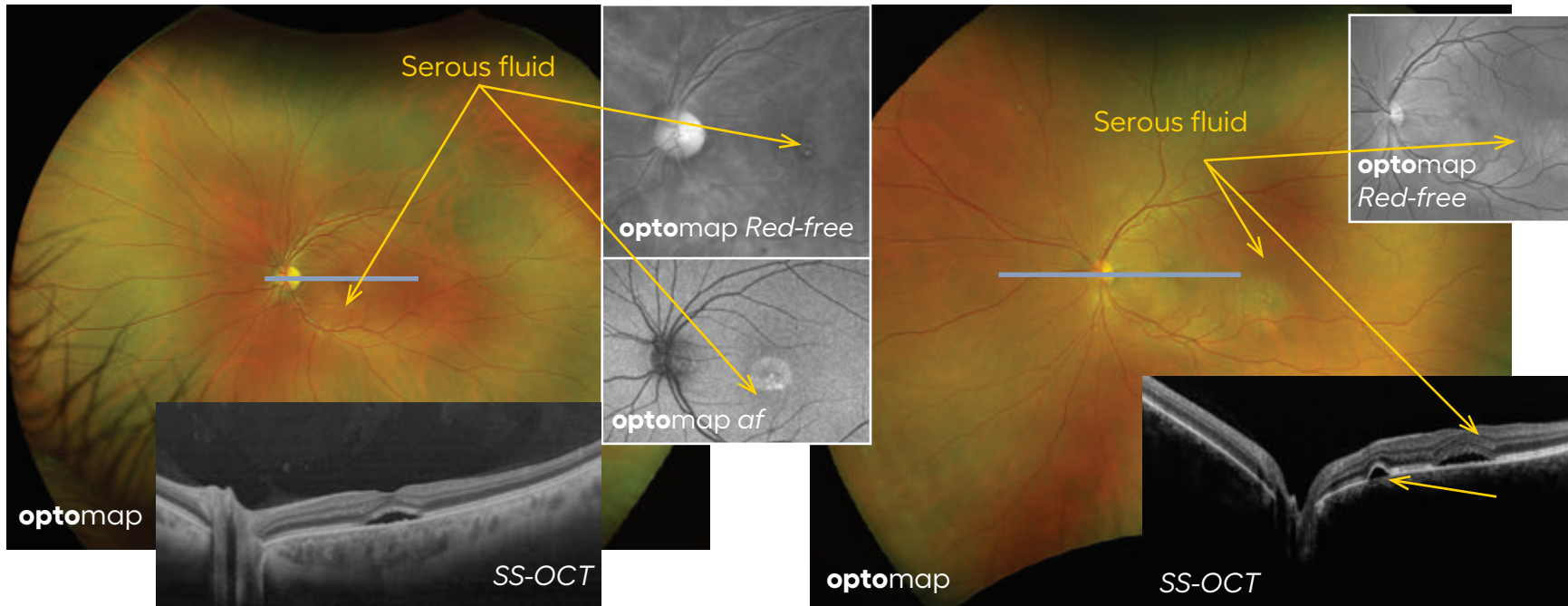
Wet AMD

is when there is choroidal neovascularization (CNV) present in or below the retina. These new vessels leak fluid into the retina causing edema and can lead to blindness.

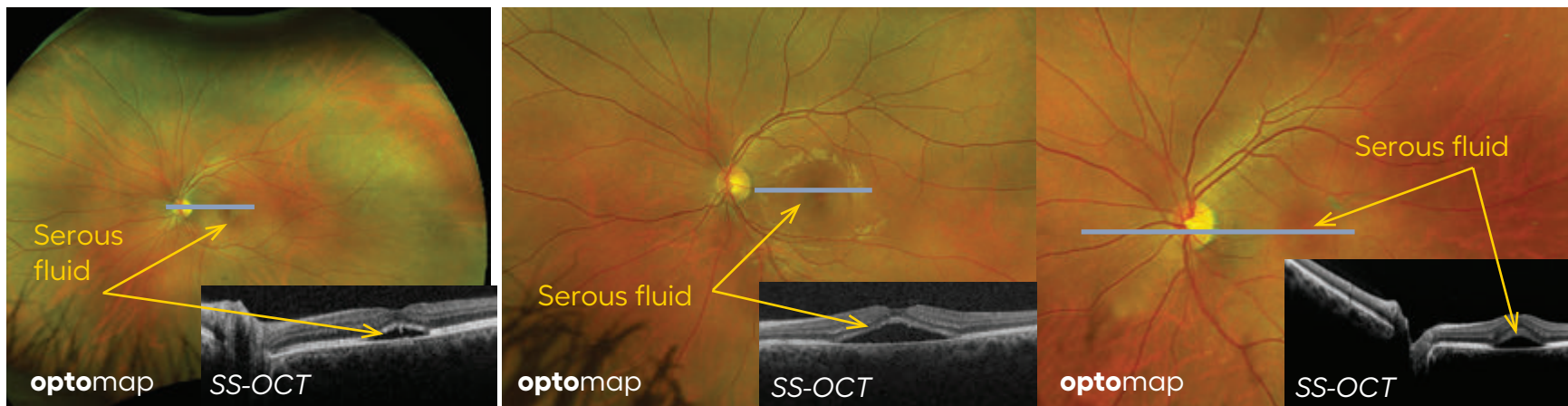


Central Serous Retinopathy, Serous Chorioretinopathy (CSR)

is a blister-like elevation of sensory retina in the macula, with a localized detachment from the pigment epithelium. This results in reduction and/or distortion of vision that usually recovers within a few months.



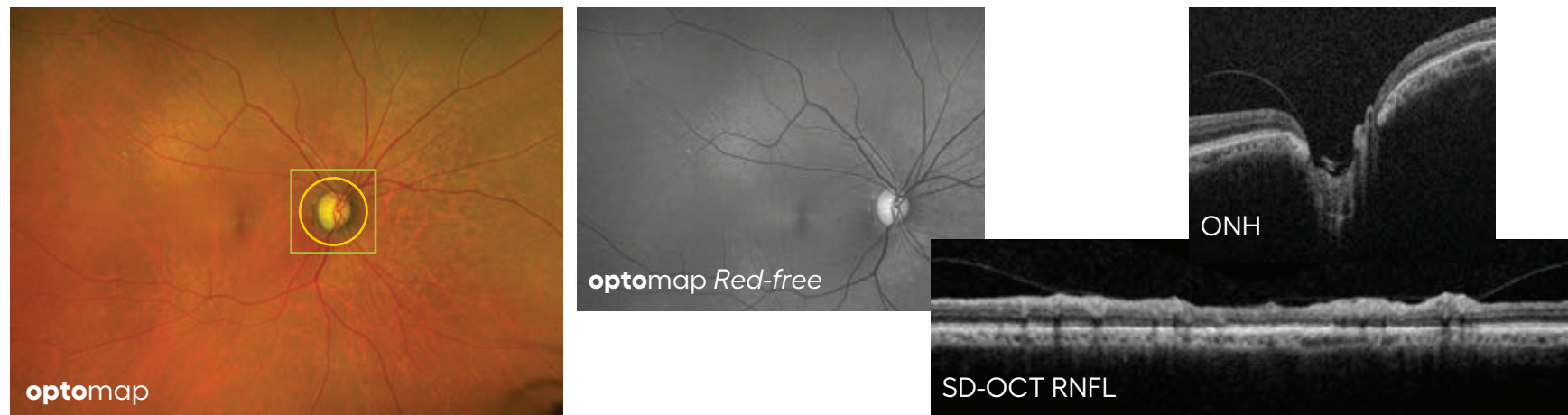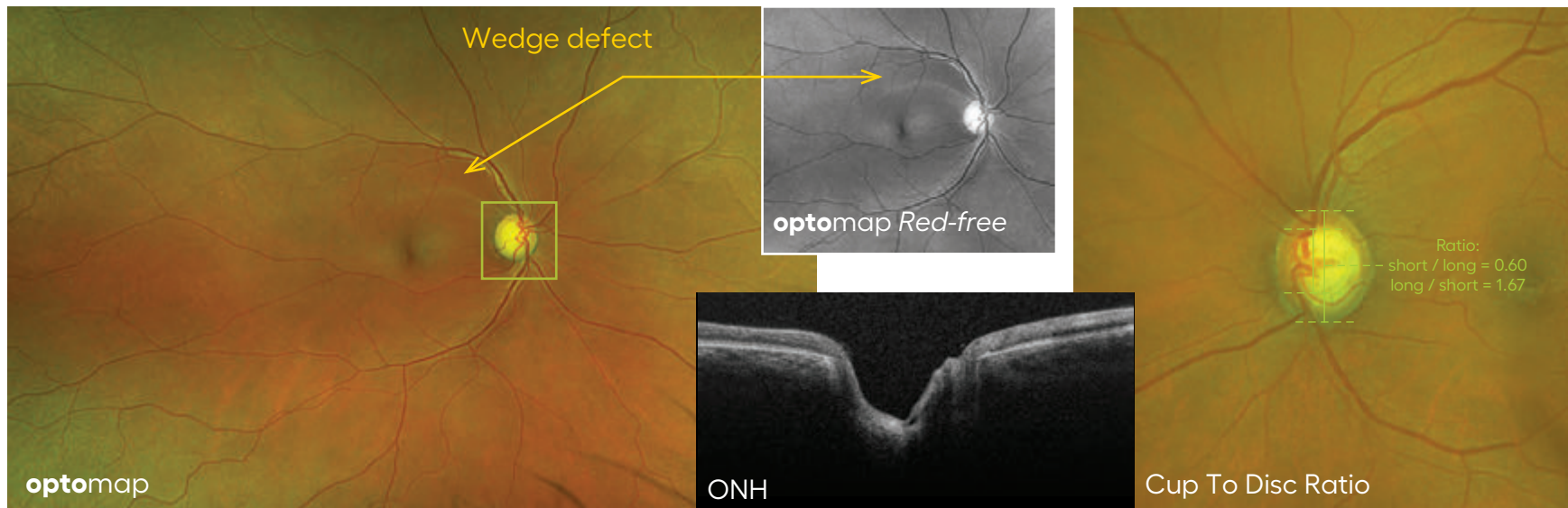
Pigment epithelial detachment (PEDs) are characterized by separation between the RPE and Bruch's membrane.



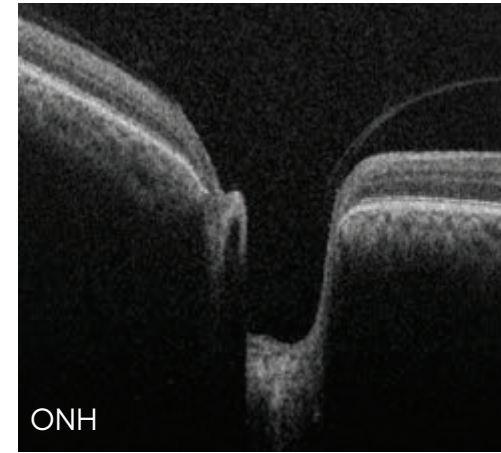
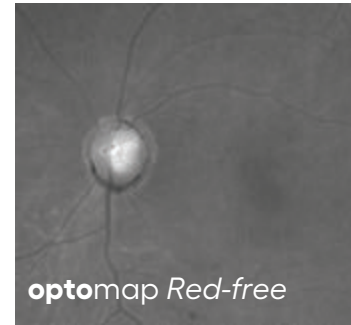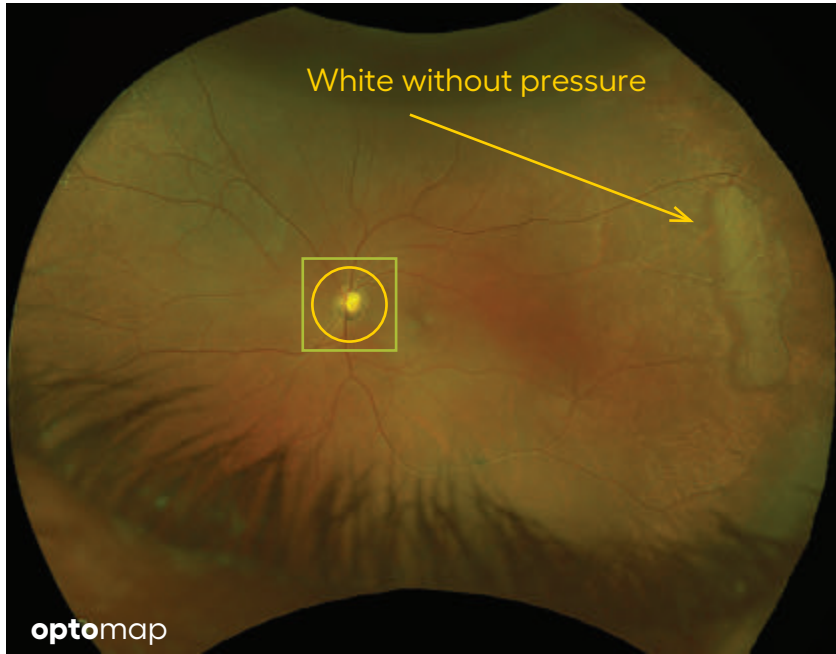
Glaucoma

is a progressive optic neuropathy where ganglion cells prematurely die resulting in a thinning of the Retinal Nerve Fiber Layer (RNFL), cupping of the optic nerve, and visual field defects. Wedge-shaped defect may be visualized in the RNFL.

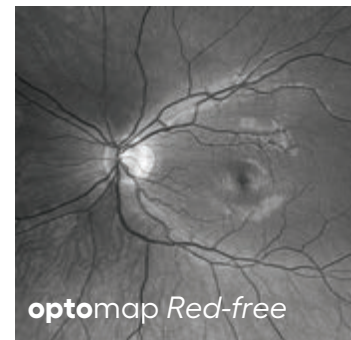
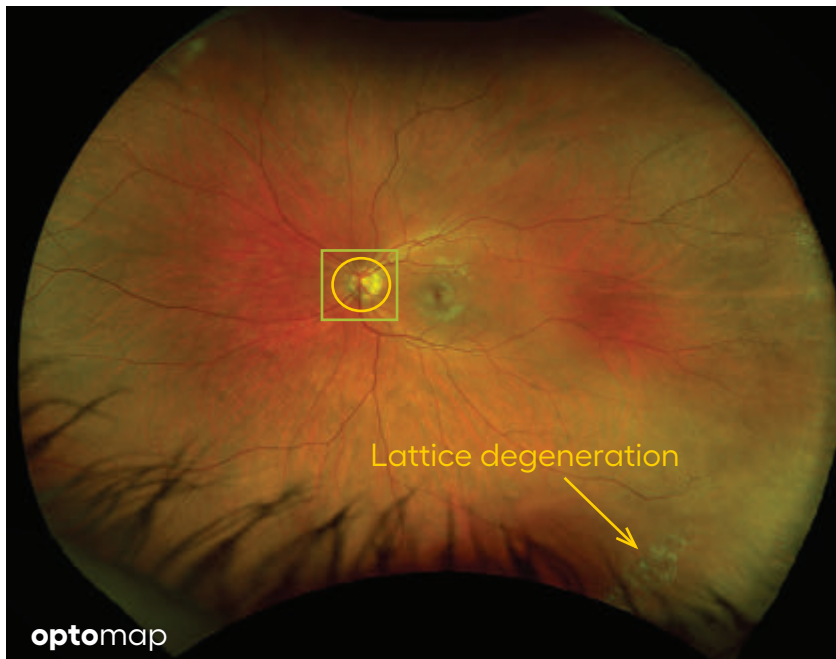
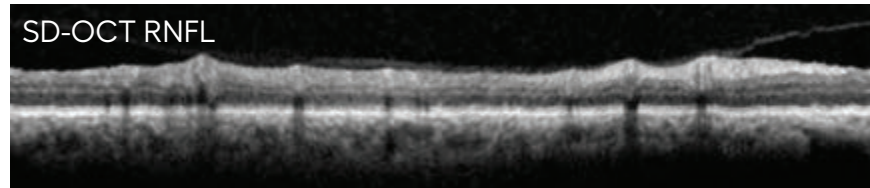
Monaco software provides the ability to measure cup to disc ratio, segment the OCT layers and assess thinning of the RNFL.



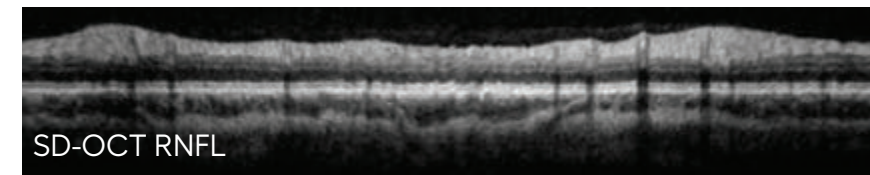
Glaucoma



Glaucoma – deep cup with media opacity



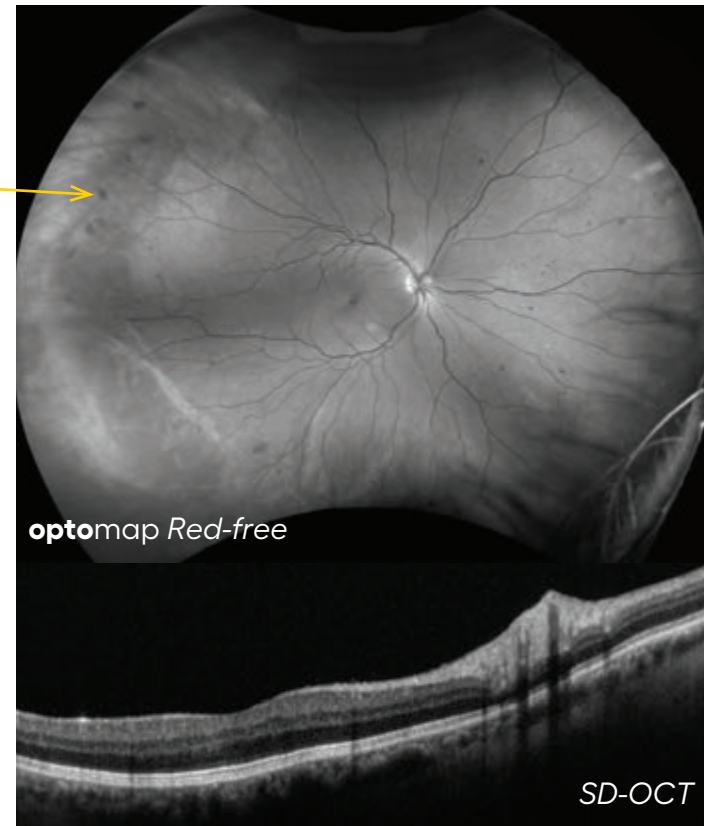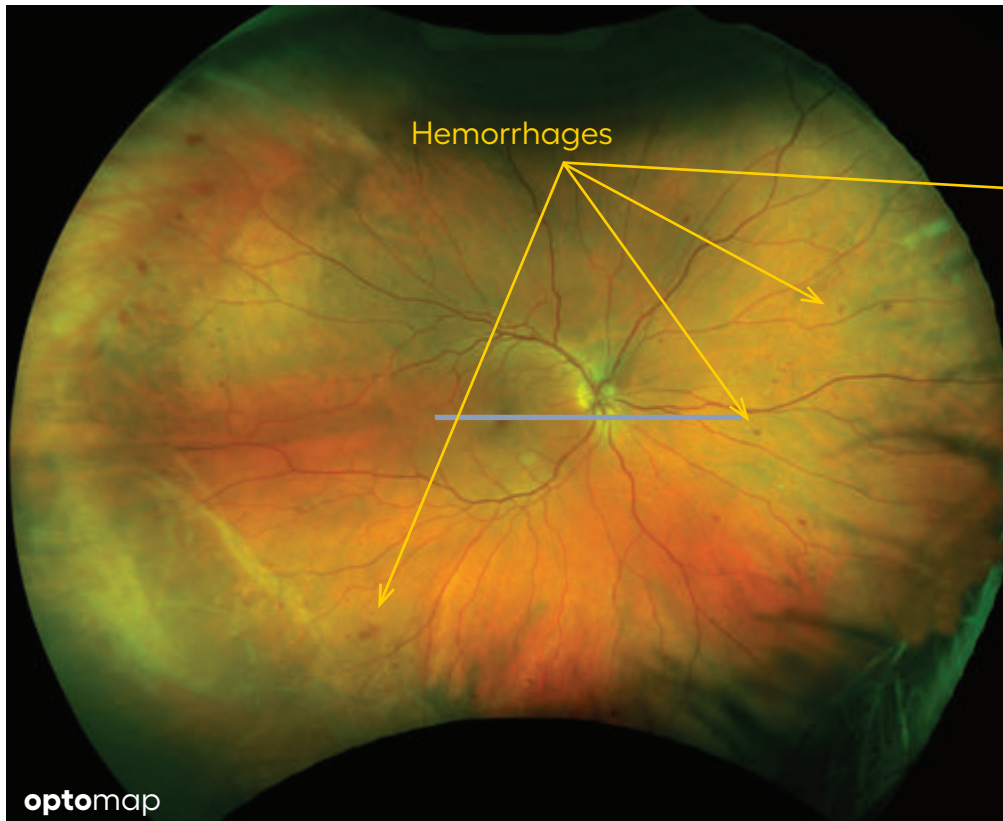
Glaucoma – shallow cup



Diabetic Retinopathy (DR)

is an ocular disease caused by diabetes mellitus. There are many stages of DR ranging from mild to severe which can lead to blindness.

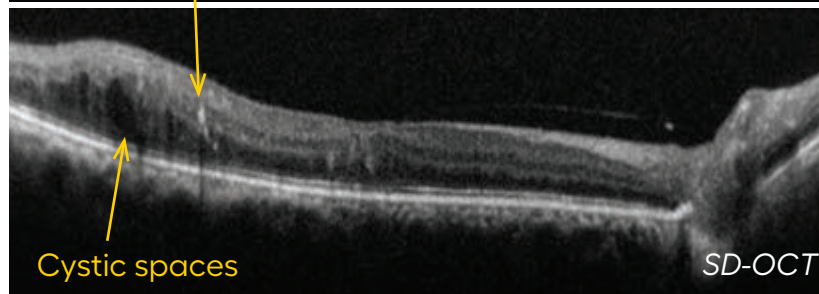
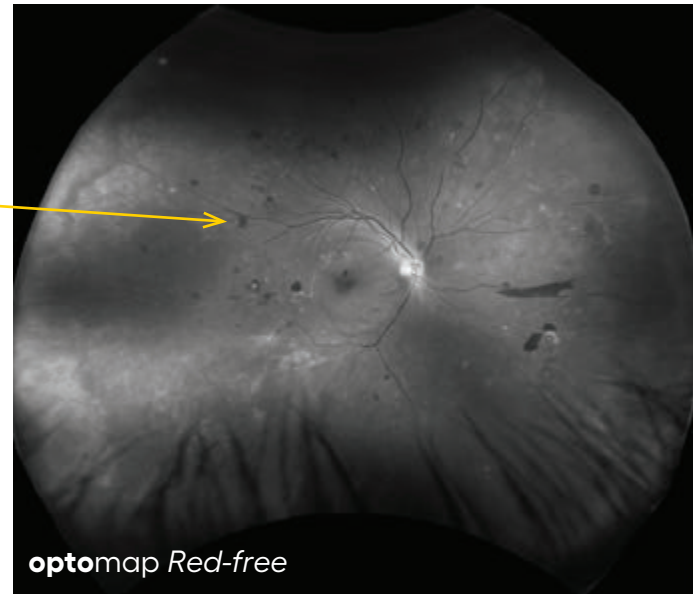
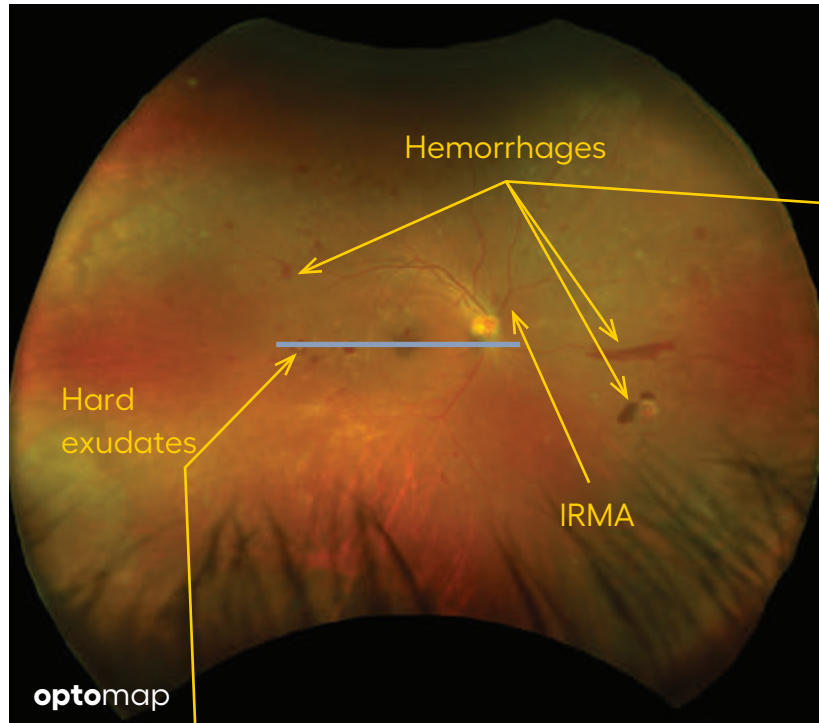
Non-proliferative diabetic retinopathy (NPDR) is the early stage of diabetic retinopathy where there is no neovascularization but there are other lesions such as hemorrhages and microaneurysms.



optomap ultra-widefield images and OCT are complementary technologies showing different pathological features of diabetic retinopathy disease.

Proliferative Diabetic Retinopathy (PDR)

which means neovascularization is present and the new blood vessels are typically leaking fluid and blood into the retina.

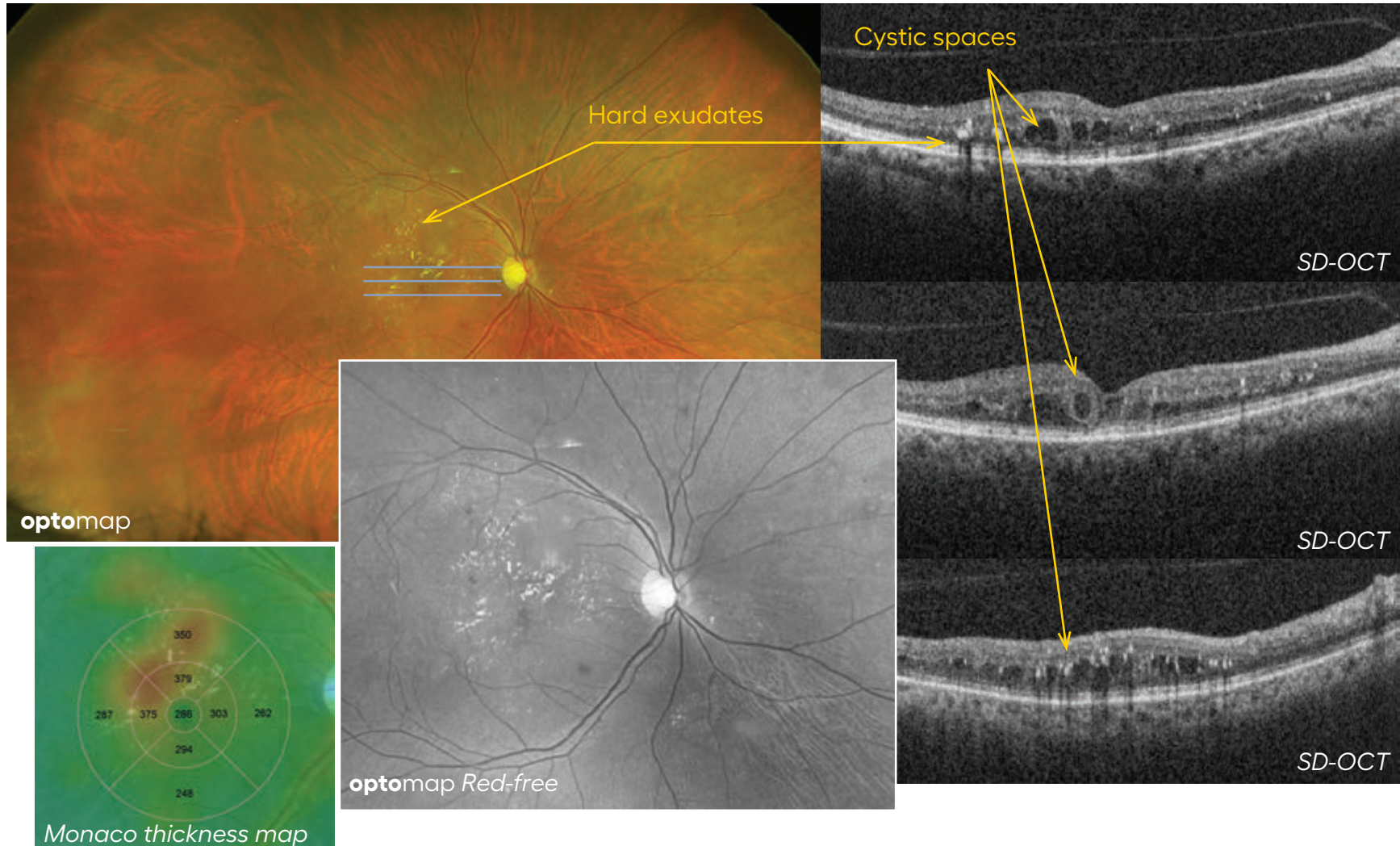


OCT can illuminate degree and extent of edema that is present, while color UWF images can identify predominantly peripheral lesions which are associated with a higher risk of progression to PDR.¹

References: 1. Silva et al Peripheral Lesions Identified on Ultrawide Field Imaging Predict Increased Risk of Diabetic Retinopathy Progression over 4 Years. Ophthalmology, 2015

Diabetic Macular Edema (DME)

is retinal swelling and cyst formation in the macular area. This can result in temporary decreased vision or permanent vision loss. DME will appear as areas of thickening on an OCT; this may be diffuse fluid which will appear dark or within cysts.



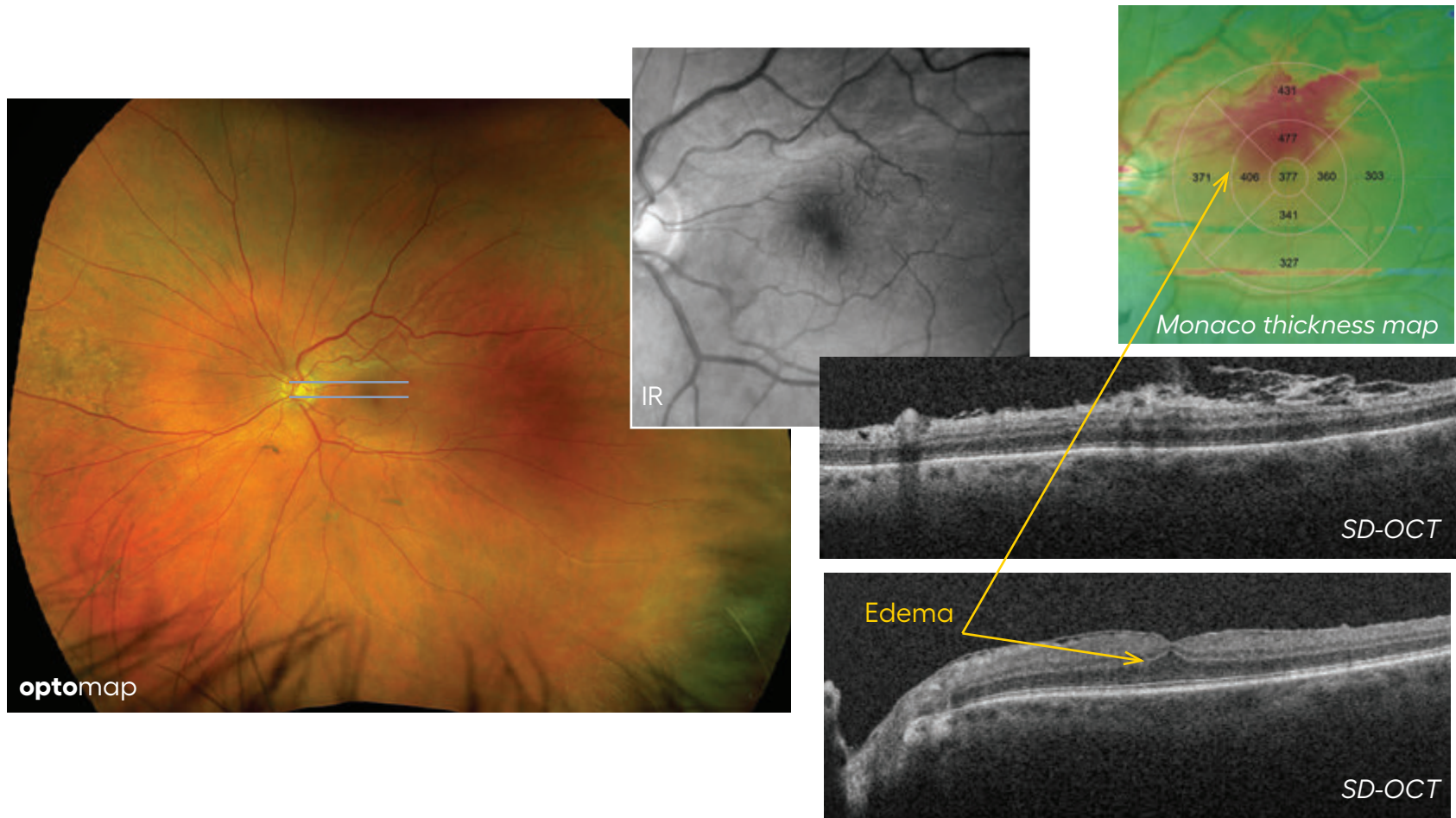
Monaco segmentation generates a thickness map which demonstrates the presence of fluid as well as provides a relative thickness calculation. Areas that appear red are thicker than those in green.

Retinal Hemorrhage

is the abnormal bleeding of the blood vessels in the retina often found in diabetic retinopathy. Dot and blot hemorrhages are tiny round hemorrhages in the retina, usually in the outer plexiform layer.

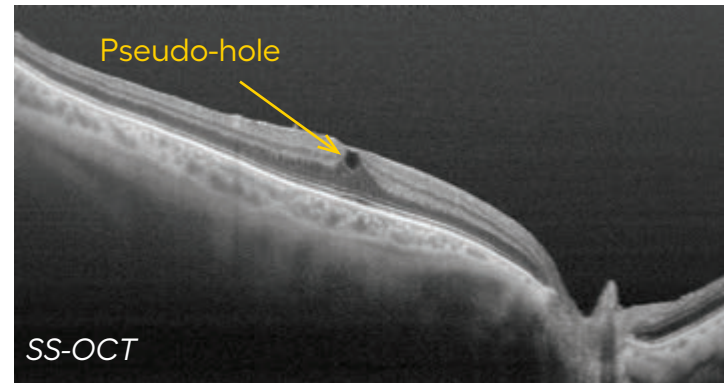
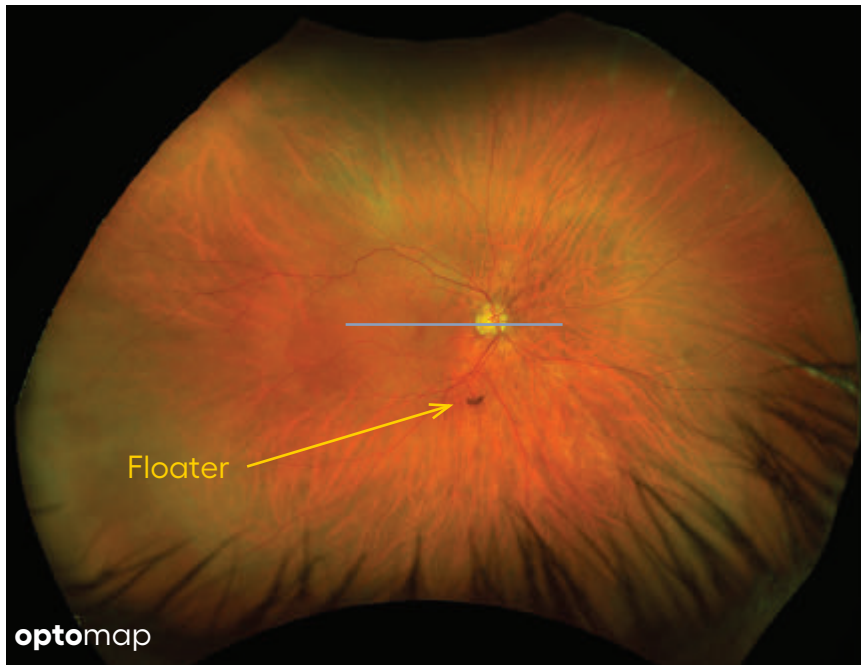
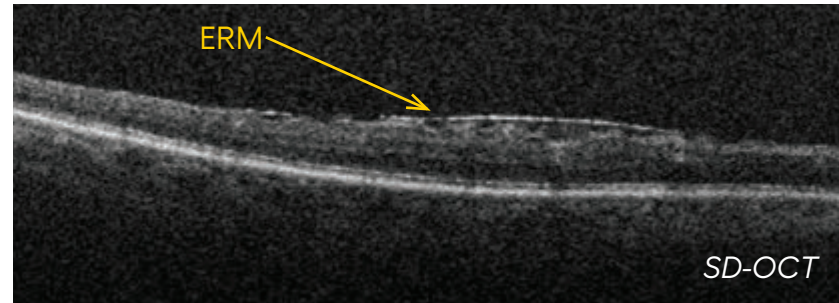
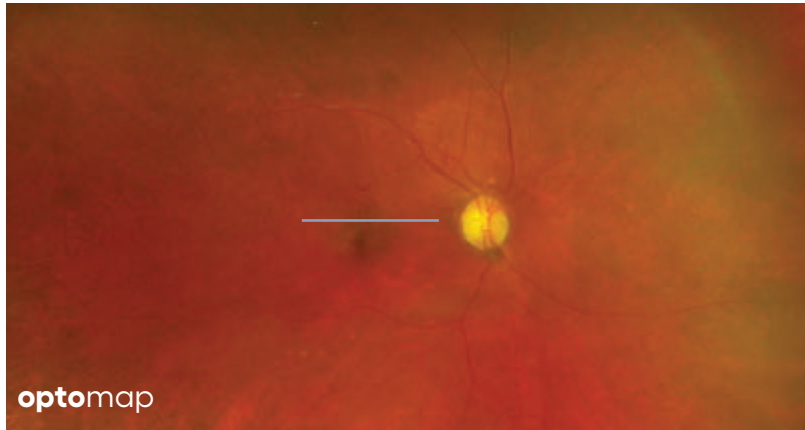
Neovascularization is the abnormal formation of new blood vessels, usually in or under the retina or on the iris surface. Neovascularization of the optic disc (NVD) are new vessels growths at the optic disc and neovascularization elsewhere (NVE) occurs outside of the optic disc.

Microaneurysms are focal dilation of the venous end of retinal capillaries. These appear in the retinal vessels as a small round red spot resembling a tiny, deep hemorrhage.



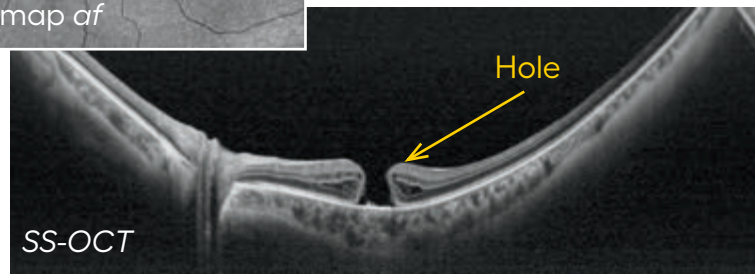
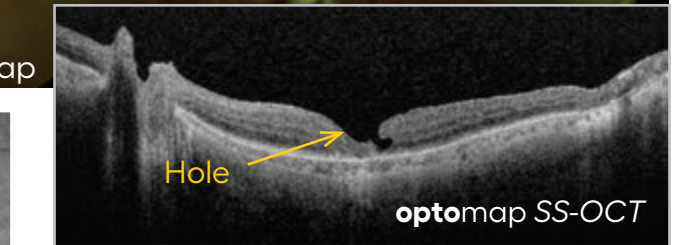
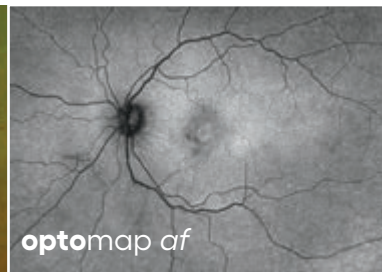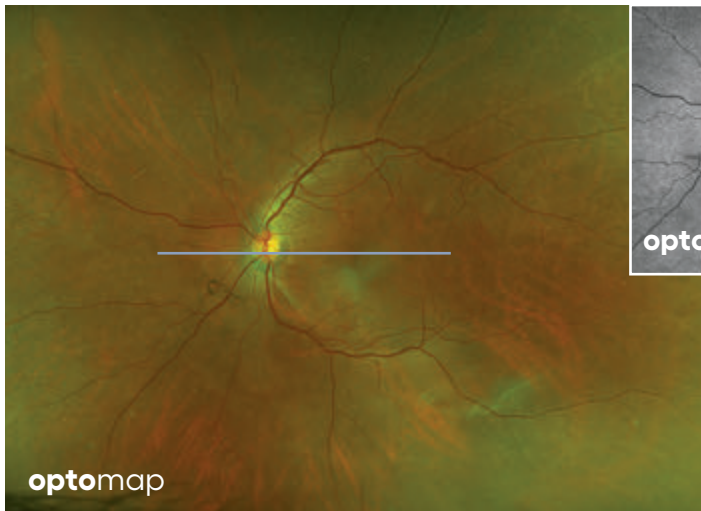
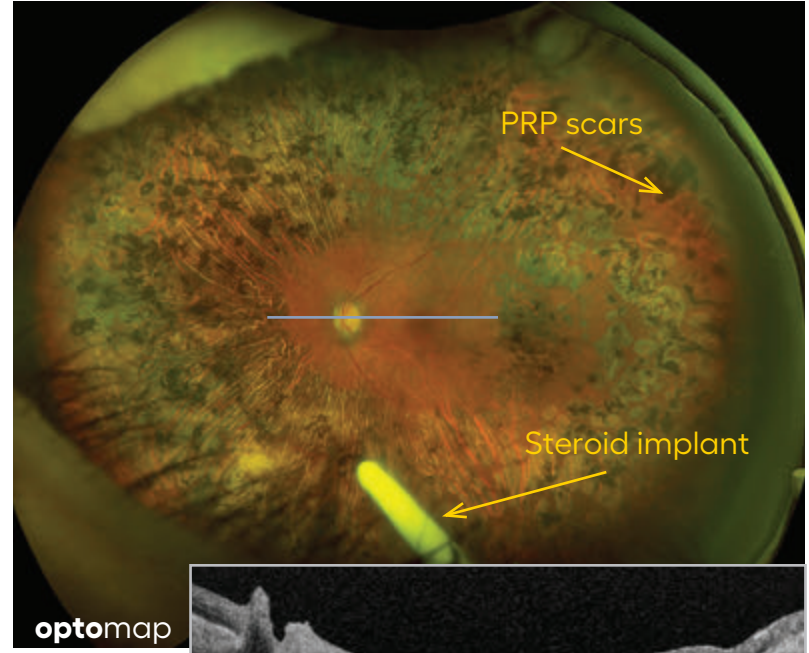
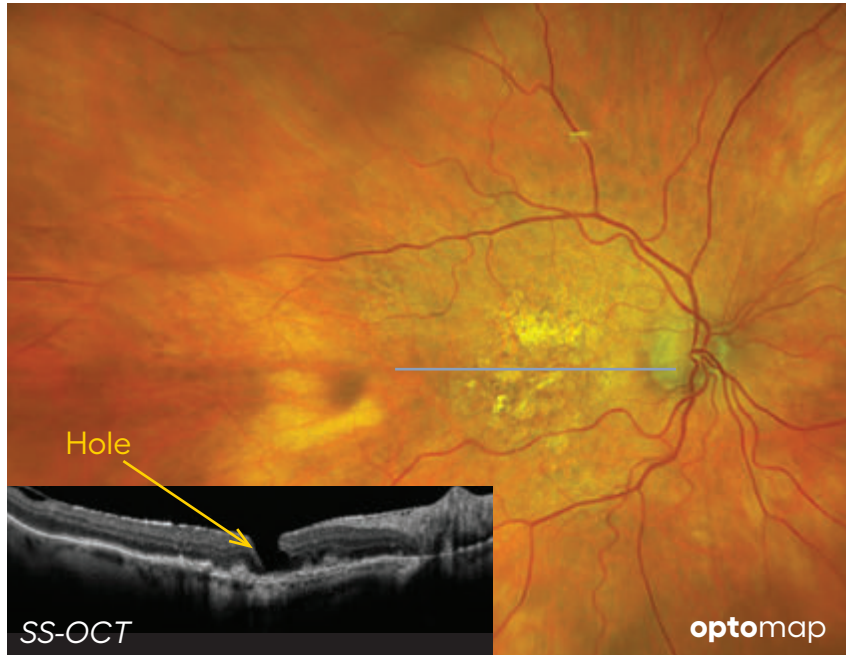
Epiretinal Membrane (ERM)

is a thin sheet of fibrous tissue that can develop on the surface of the macular area of the retina and can cause a disturbance in vision. It can sometimes pull on the retina and cause vitreo-macular traction (VMT) potentially leading to a macular hole.



Macular Hole

is a small break in the macula which may cause distorted or blurred vision. A Pseudo-macular hole is not a true break but merely tension in the retina which can appear like a hole on examination but is distinguished more clearly with OCT imaging.

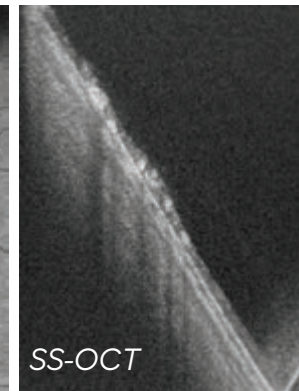
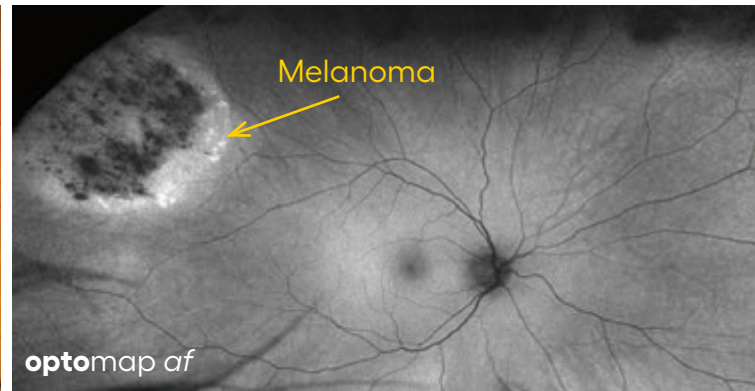
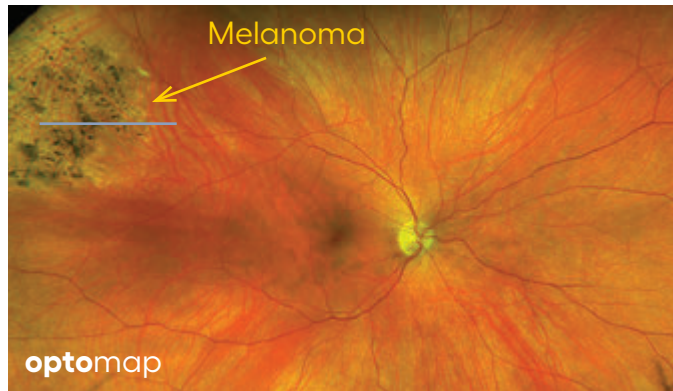
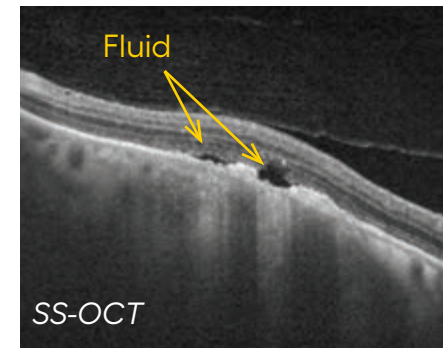
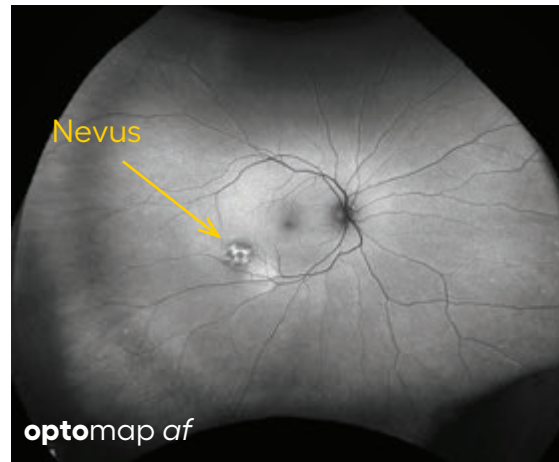
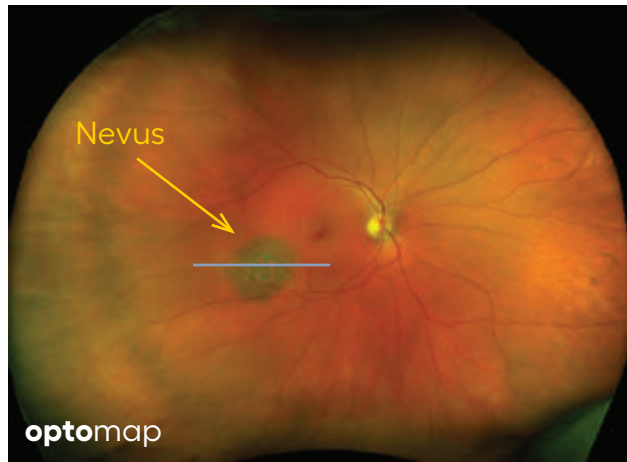


Pigmented Lesions

including nevi and tumors benefit from multimodal imaging which can help discern the location, size and whether fluid is present.

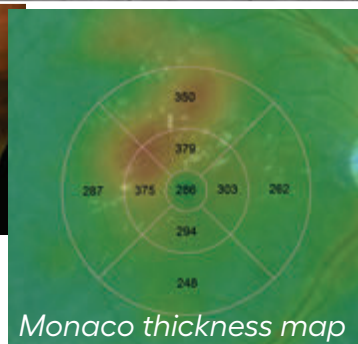
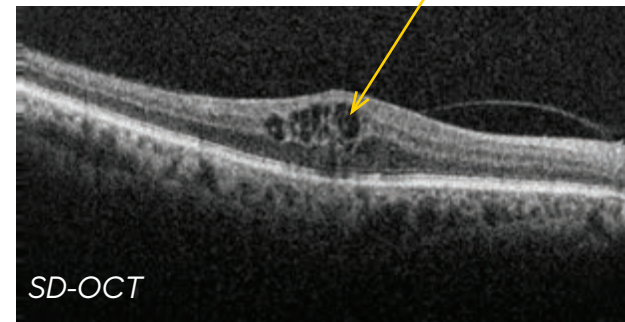
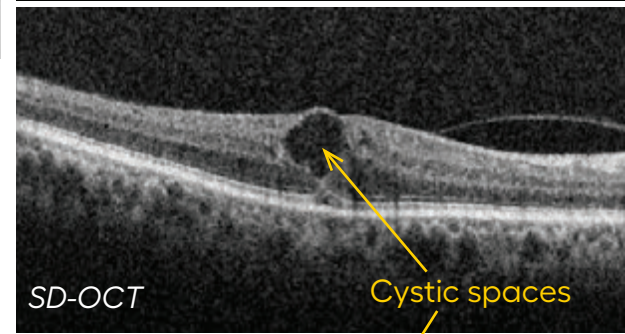
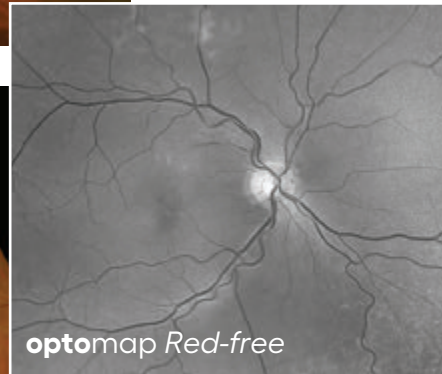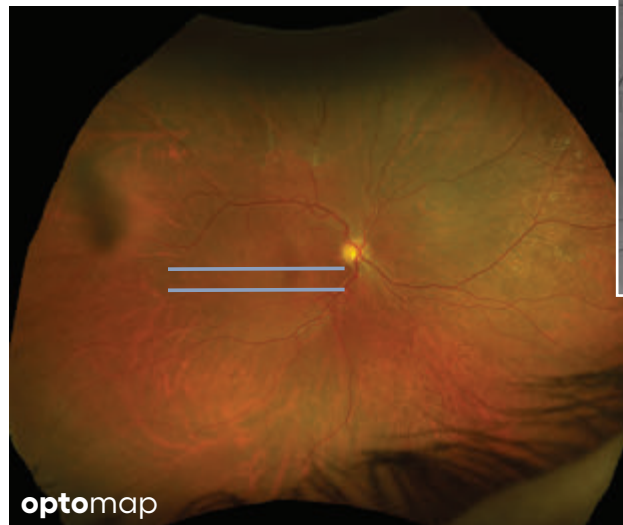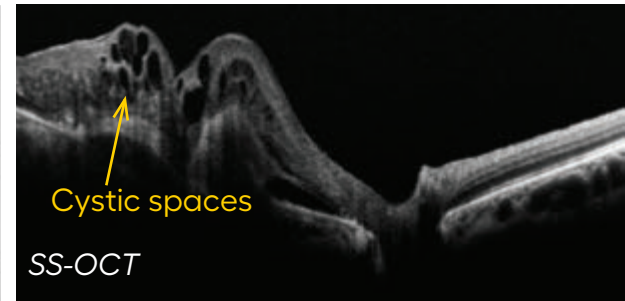
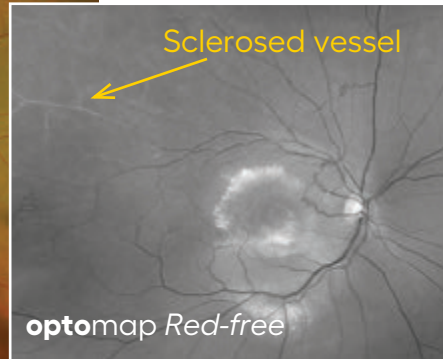
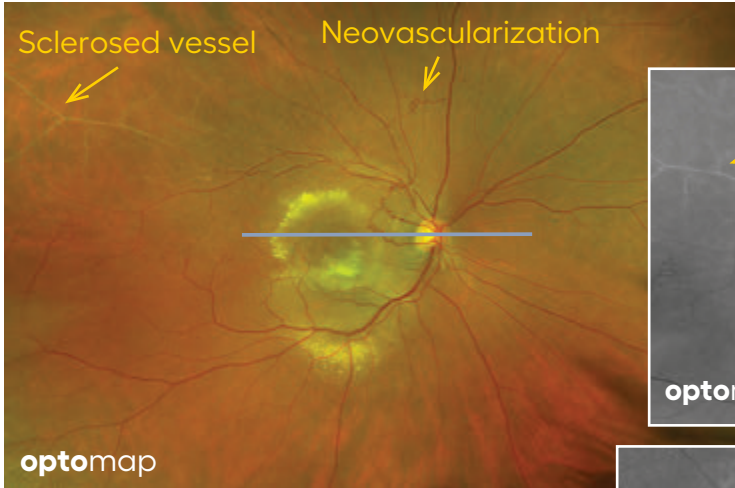
Choroidal nevus is an accumulation of melanocytes in the choroid. They are a space occupying mass or a benign melanoma. Choroidal nevi are slate gray in color, have indistinct margins, and may be slightly elevated (1-2 diopters). Since they are in the choroid, they are usually only seen in the red separation and not the green. The green separation may show the RPE degeneration associated with nevi which is seen as pigment mottling and drusen.

Choroidal melanoma arises from the pigmented cells of the choroid of the eye and is not a tumor that started somewhere else and spread to the eye.



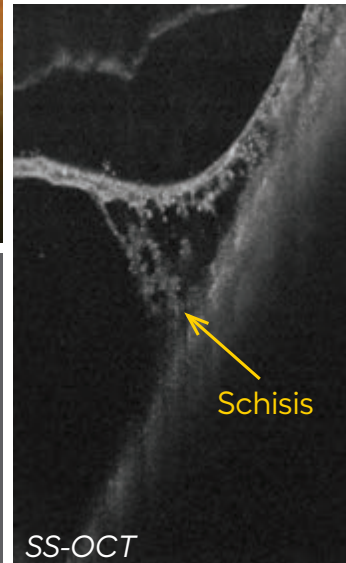
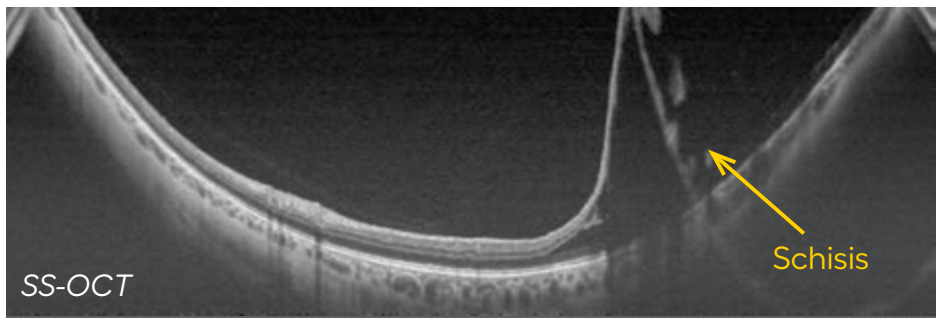
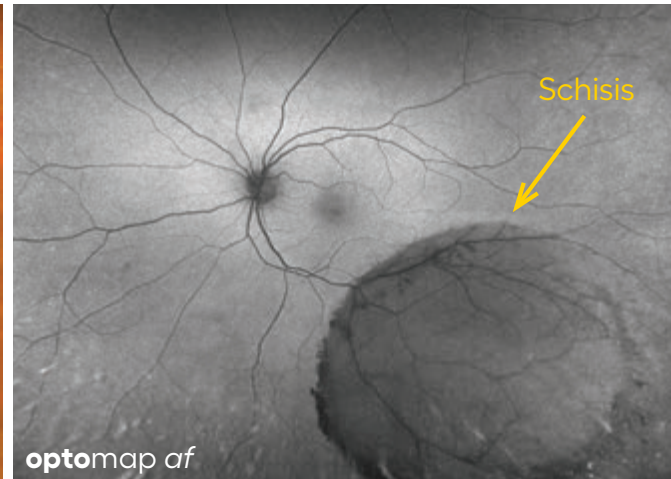
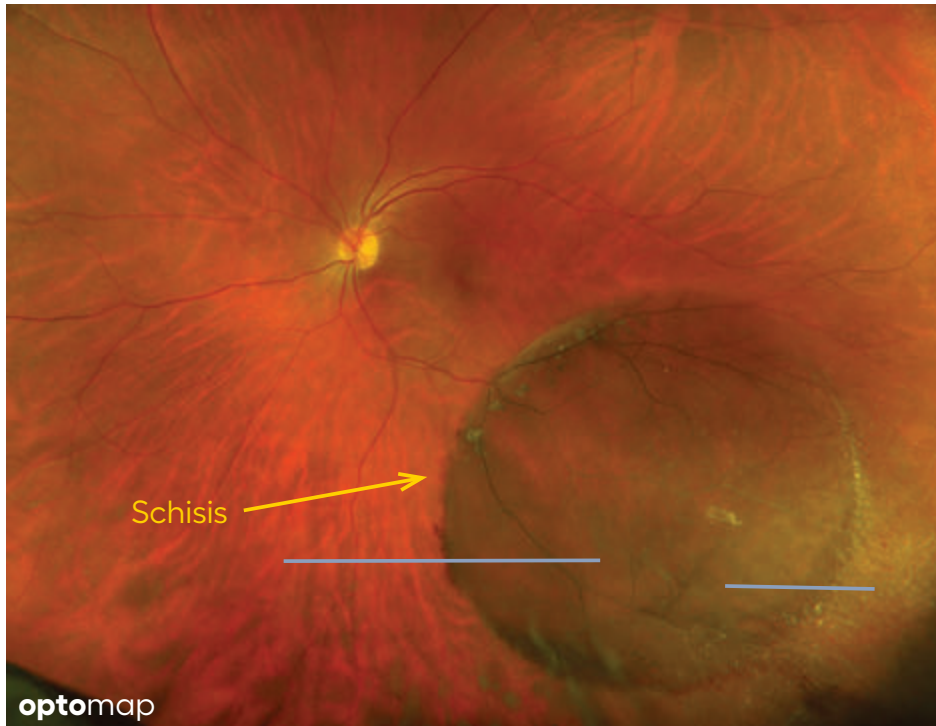Retinal Vein Occlusion (RVO)

is a retinal vascular disorder in which a blockage occurs that can involve the central retinal vein (CRVO) or a major branch of the central vein (BRVO). These blockages occur where retinal arteries that have been thickened or hardened by atherosclerosis cross over and place pressure on a retinal vein. When a retinal vein is blocked, it cannot drain blood from the retina leading to widespread hemorrhages and leakage of fluid. Cystoid macular edema (CME) can also be present which is visible on OCT and visual acuity may be greatly decreased.



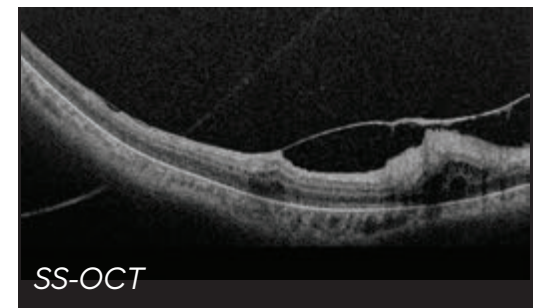
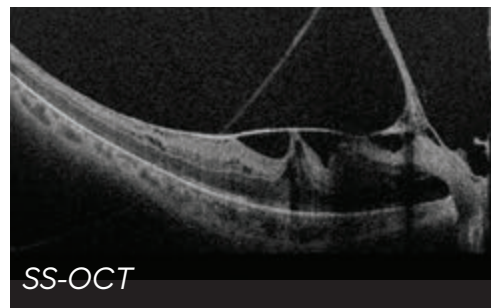
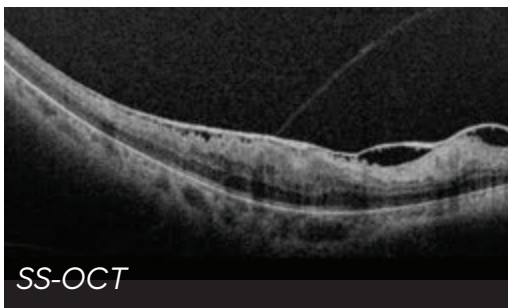
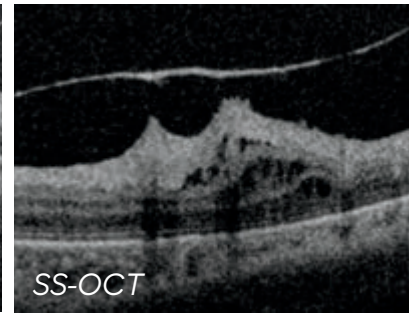
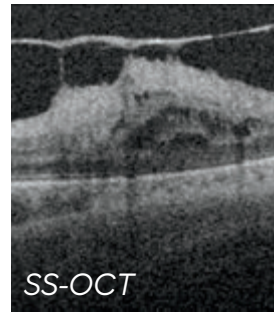
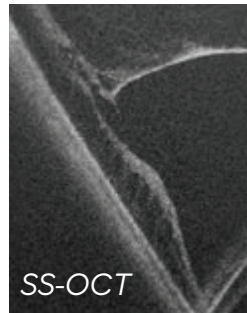
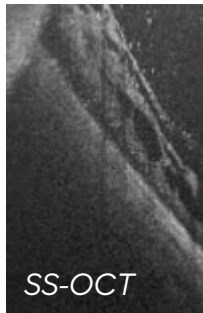
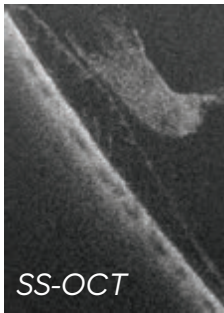
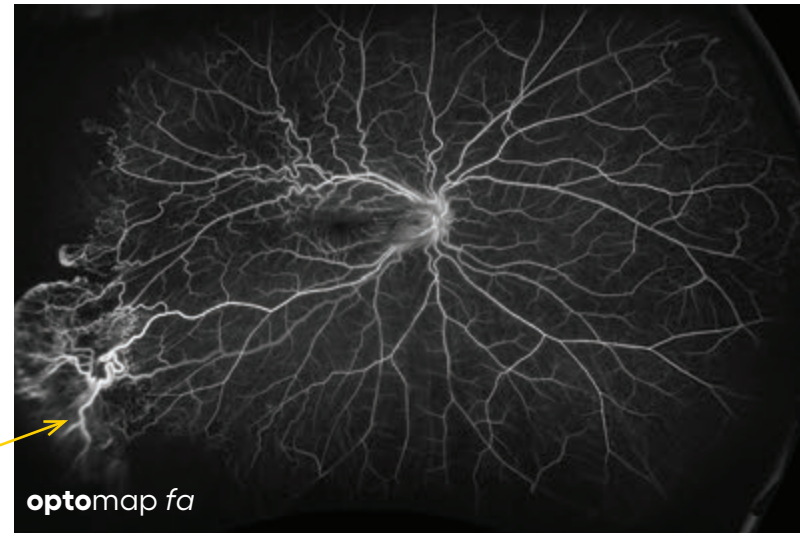
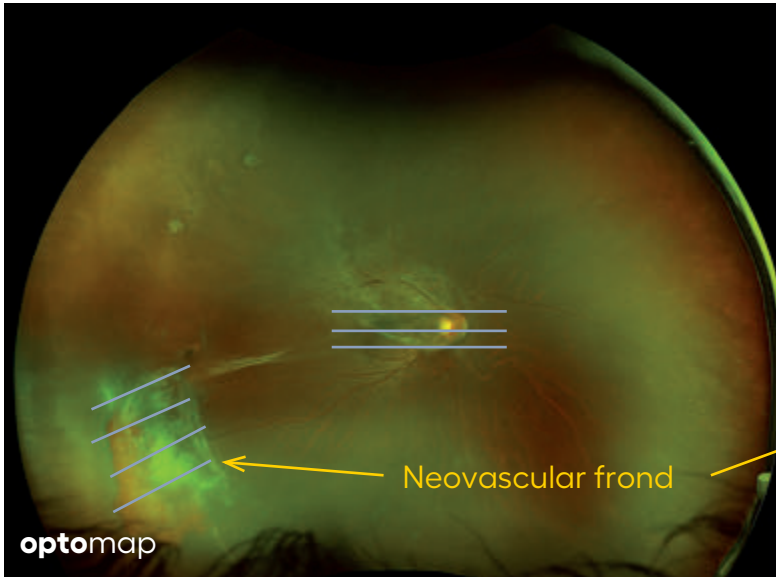
Retinoschisis

is a splitting of the sensory retina into 2 layers; an inner and outer layer. The etiology is most likely vitreous traction that physically pulls the retina apart. The posterior border of a retinoschisis is convex to the posterior pole, because a retinoschisis forms like blowing up a balloon in the peripheral retina (as seen in most retinal detachments). The inner layer can be shallow or bullous into the vitreous cavity. The inner layer may or may not have retinal vessels in it (depending if the retinal vessels pass into the inner layer or outer layer). Since the vessels in the inner layer are above the retinal surface like vitreous floaters, they can block the exiting light and produce a shadow effect dark vessels.



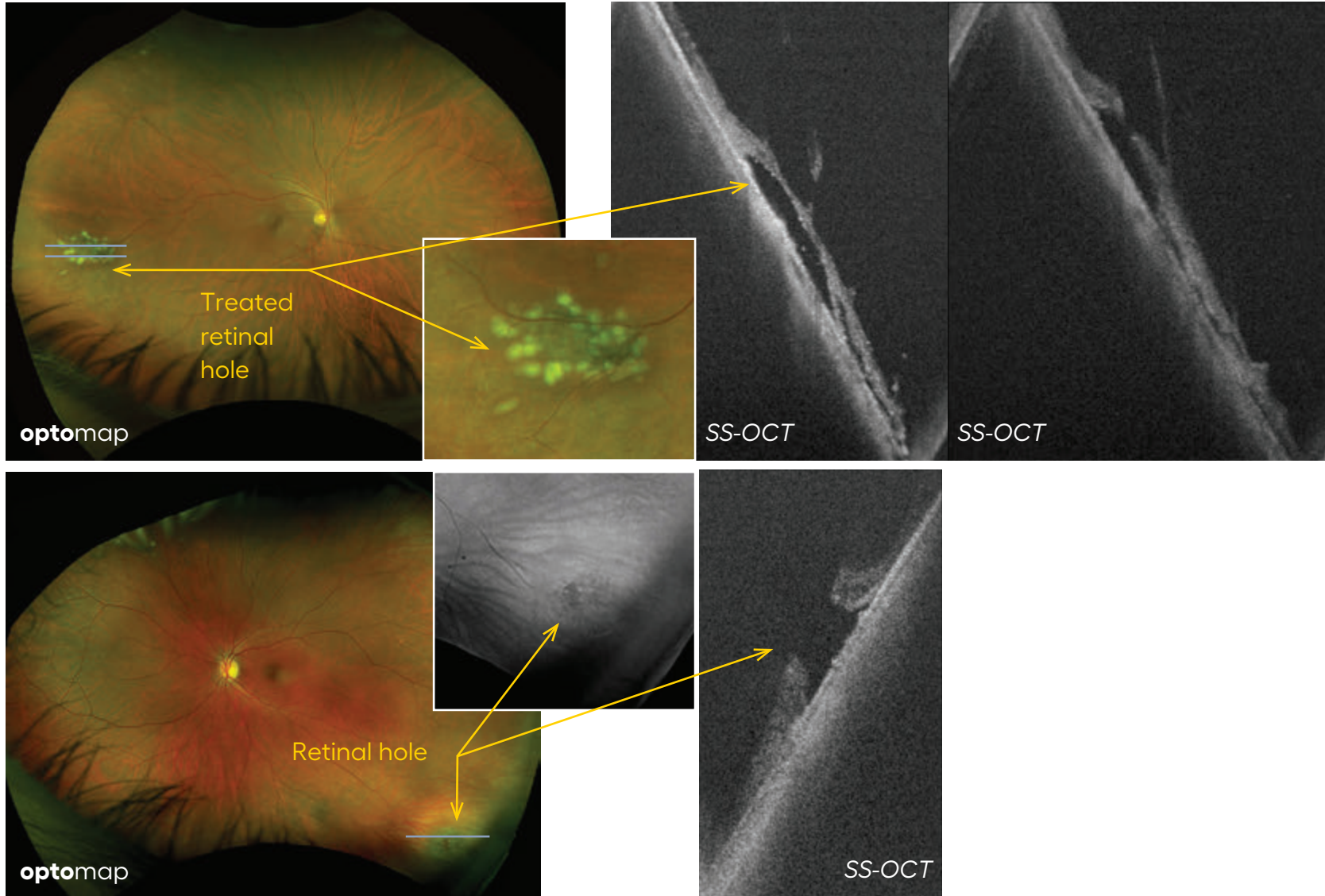
Sickle Cell Retinopathy

the blockage of blood vessels in the retina and choroid results in abnormal blood vessel growth and thinning of the retina. These physical changes and their consequences can impair vision.



Retinal Tears, Holes and Breaks

are small areas of the retina that are torn. These areas, called retinal breaks, can lead to a retinal detachment. Retinal breaks are often caused by traction from the vitreous, the gel that fills the back of the eye. Traction can occur as the vitreous pulls away from the retina, which occurs with age, trauma, surgery, inflammation, and near-sightedness.



Vitreous

unlike *SD-OCT*, Swept-source OCT provides high sensitivity throughout the B scan window, from top to bottom. This allows great visualization of the vitreous as well as the choroid in a single scan.

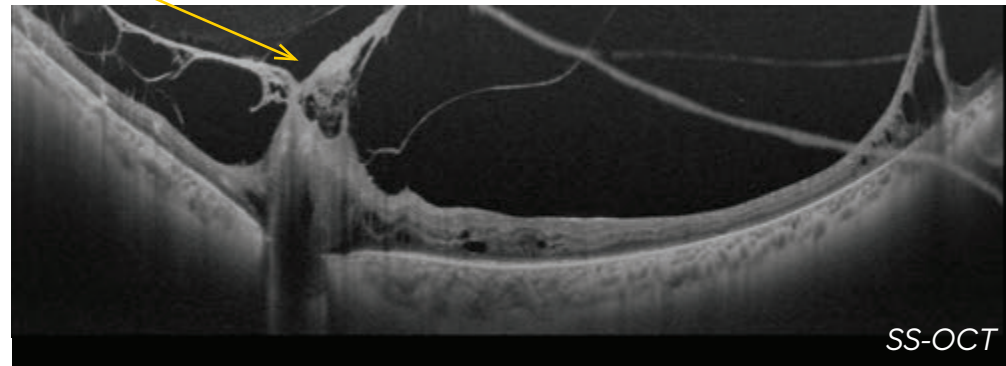
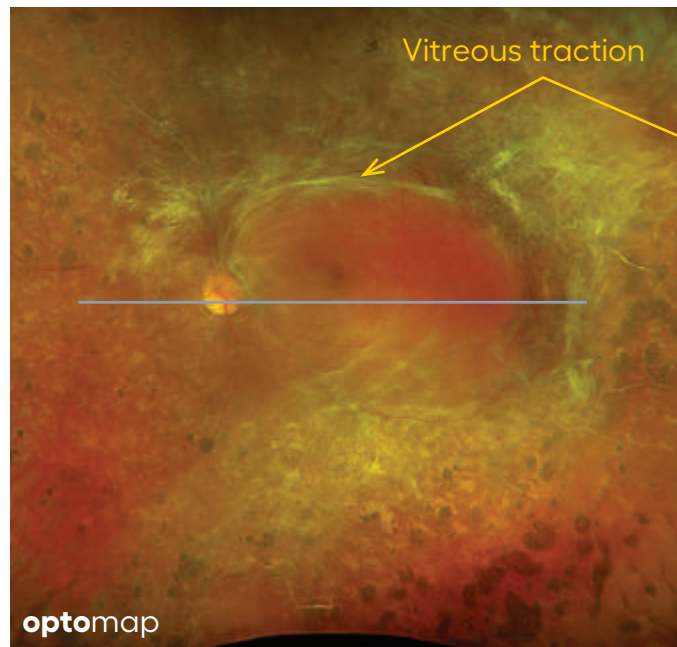
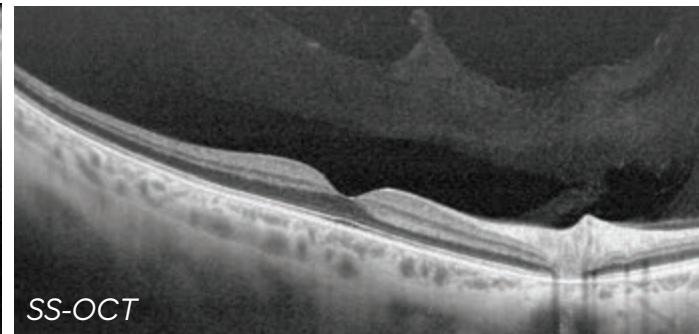
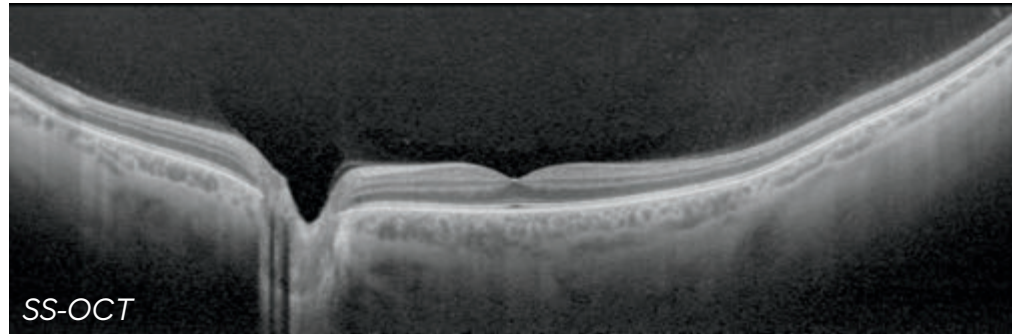


Image Acknowledgements

All images are courtesy of:

Professor Paulo Stanga
The Retina Clinic London
London, UK

Dr. David Brown
Retina Consultants of Texas
San Antonio, TX

Reference for Definitions

Dictionary of Eye Terminology. Sixth Edition. 2012.
Barbara Cassin and Melvin L. Rubin, MD.
Triad Communications, Inc.

The Retinal Atlas. Second Edition. 2017
Bailey Freund, MD; David Sarraf, MD; William F. Mieler, MD;
Lawrence A. Yannuzzi, MD
Elsevier

Optical Coherence Tomography of Ocular Diseases. Second edition. 2004
Joel Schuman MD, Carmen Puliafito MD, James Fujimoto PhD
Slack Incorporated

The **opto**map OCT Diagnostic Atlas: A Retinal Reference Guide was created
by the Optos Clinical Team and reviewed by Tunde Peto, MD, PhD.

Contact clinical@optos.com for additional educational questions

Optos, part of Nikon Healthcare is the leading retinal imaging company committed to saving sight and saving lives worldwide.

The company was founded by a father determined to find a better way to detect eye disorders and diseases, following his son's loss of sight in one eye despite regular eye examinations. Optos has led the field with its high resolution ultra-widefield (UWF™) **optomap®** imaging, which captures approximately 82% and 200° of the retina, something no other device can do in a single image.

Optos has since expanded its unrivaled UWF devices to offer integrated multimodal imaging solutions including Optical Coherence Tomography (OCT), data management software and other offerings to facilitate accessibility in any healthcare setting.

Thousands of published clinical studies have demonstrated the long-term value of **optomap** multimodal imaging in early detection, management and effective treatment of disorders and diseases such as retinal detachments and tears, glaucoma, diabetic retinopathy, and age-related macular degeneration.



Optos UK/Europe
+44 (0)1383 843350
ics@optos.com

Optos North America
800 854 3039
usinfo@optos.com

Optos DACH
DE: 0800 72 36 805
AT: 0800 24 48 86
CH: 0800 55 87 39
ics@optos.com

Optos Australia
+61 8 8444 6500
auinfo@optos.com

Contact us:

