

# Advances in Imaging— Single-Capture UWF Technology

---

Experts discuss  
applications and benefits  
of UWF imaging



Dilsher Dhoot, MD



William Lahnert,  
MD, FACS



Carlos Martinez, MD



John W. Kitchens, MD

# Advances in Imaging— Single-Capture UWF Technology

By Dilsher Dhoot, MD, John W. Kitchens, MD, William Lahners, MD, FACS, Carlos Martinez, MD

In late 2021, a panel of expert ophthalmologists discussed the clinical applications and practical benefits of single-capture ultra-widefield (UWF™) imaging from Optos Inc. The interactive seminar, facilitated by John W. Kitchens, MD, covered multiple topics, including applications of whole eye assessment with UWF imaging and the benefits of UWF imaging in cataract/refractive practices. During the program, the 300 attendees were polled regarding their experience with UWF imaging. The highlights from the survey, presented in the sidebar, add to our understanding of the impact of UWF on eye care.

## Whole Eye Assessment With UWF Imaging

**Dilsher Dhoot, MD**

*California Retina Consultants*

Traditional fundus camera technology is nearly 100 years old. First developed in 1926 with a 20-degree field of view,<sup>1</sup> it quickly advanced to 30 degrees. This is still used by many clinics and studies today, including the Early Treatment Diabetic Retinopathy Study (ETDRS), which standardized a montage of seven, 30-degree images. This seven-standard field (7SF) montage provides a

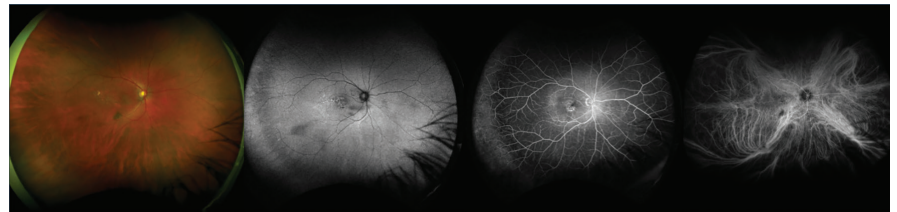


Figure 1: Ultra-widefield multimodality

IMAGE COURTESY RETINA CONSULTANTS OF HOUSTON

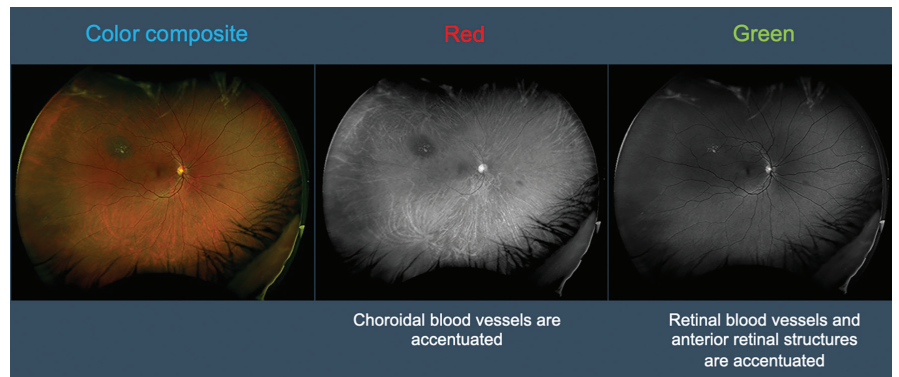


Figure 2: Ultra-widefield Red and Green cSLO

IMAGE COURTESY RETINA MANCHESTER ROYAL EYE INFIRMARY

reasonable view of the posterior pole, but there are practical limitations. 7SF does not show the peripheral (posterior to the vortex veins) retina. Additionally, capturing seven images requires substantial photographer expertise, patient compliance, and time. Because of this, the method is not effective for time-based studies such as fluorescein or indocyanine green (ICG) angiography.

UWF technology is available with all key retinal multimodalities. In addition to color, the Optos technology offers autofluorescence, fluorescein angiography, ICG

angiography, and OCT. These color images, produced using red and green wavelengths, can be viewed in full color and across the spectrum from red-only (which accentuates choroidal vasculature) to green-only (excellent for identifying retinal blood vessels and anterior retinal structures). Serial image overlays also make it easy to see changes over time in lesions, such as choroidal nevi or the progression/regression of nonperfusion.

In recent years, an increasing number of doctors have moved to UWF imaging because the field of view (FOV) allows them to assess

virtually the “whole eye,” rather than just the macula or posterior pole. With single-capture UWF technology, we can quickly and easily acquire a 200-degree FOV of the retina. The International Widefield Study Group defined UWF as an image centered on the fovea, showing the vortex ampullae and retina anterior to them in all 4 quadrants.<sup>2</sup> Widefield imaging, on the other hand—though centered on the fovea as well—can only image as far as the posterior to the vortex ampullae.

With over 2,000 peer-reviewed publications documenting the impact of Optos UWF technology when diagnosing a variety of conditions, the move to UWF is well-supported by the data. When

#### MODERATOR COMMENTS

Due to COVID concerns and the need to manage increased demand from DR and AMD patient populations, use of retinal tele-screening is increasing. In our clinic, though we still dilate almost every patient, **optomap** is part of our comprehensive exam because it provides so much information in one frame.

managing diabetic retinopathy (DR) and macular degeneration, doctors have historically focused on the central retina. Routine use of UWF imaging has changed this perspective. We now know how important it is to assess the whole retina. High-risk proliferative diabetic retinopathy (PDR) often presents with lesions, such as neovascularization and

microaneurysms, forming across the retina. With UWF, we see significantly more lesions along the periphery than with ETDRS montages.<sup>3</sup> These lesions, which could otherwise go undetected, are now being recognized as increasing the risk of progression.<sup>4,5</sup> Even patients referred for mild PDR have shown massive peripheral ischemia when their **optomap**<sup>®</sup> is examined. There are cases where neovascularization—not always visible to the naked eye during indirect ophthalmoscopy—can be seen on UWF imaging due to the high-quality optics and FOV. With **optomap** and its proprietary software, it is now possible to mark areas of ischemia and quantify them using auto-summation of these



#### Dilsher Dhoot, MD

**Dr. Dilsher Dhoot** received his undergraduate degree with honors from U.C. Berkeley. He completed his medical degree at Oregon Health Science University. His residency was at the Casey Eye Institute, and then his fellowship training in vitreoretinal surgery at the Cleveland Clinic, Cole Eye Institute. He has published numerous book chapters and research articles in several journals, including *Ophthalmology*, *British Journal of Ophthalmology*, and *Retina*. He currently serves as a section editor for the *Retina Times*. Dr. Dhoot is currently a vitreoretinal surgeon at California Retina Consultants



#### William Lahners, MD, FACS

**Dr. William Lahners** earned his undergraduate degree from the University of Texas, and his medical degree with honors from Louisiana State University. He continued his education with a combined internship in Medicine and Surgery at the Mayo Clinic, a residency in ophthalmology at Emory University, and a fellowship at the Phillips Eye Institute in Minneapolis. Because of his vast experience with femtosecond lasers, he served on the editorial board of *Cataract & Refractive Surgery Today* magazine. In addition to his certification by the American Board of Ophthalmology, Dr. Lahners was also board-certified in LASIK by the American Board of Eye Surgery.



#### Carlos Martinez, MD

**Dr. Carlos Martinez** earned his undergraduate degree in Chemistry at Tulane University and his Master of Science degree in Theoretical Chemistry. In 1994, he received his MD and residency in Ophthalmology from the Louisiana State University (LSU) School of Medicine in New Orleans. He has over 20 years of experience in the medical and surgical treatment of eye diseases. In 1999, Dr. Martinez joined Eye Physicians of Long Beach. Now as a managing partner, he is dedicated to bringing state of the art eye care to Southern California.



#### John W. Kitchens, MD

**Dr. John W. Kitchens** is a retina specialist and partner at Retina Associates of Kentucky. He earned his undergraduate degree in both Chemistry and Biology as well as a minor in Psychology, then went on to attend the Indiana University School of Medicine. Dr. Kitchens matched into residency at the acclaimed University of Iowa Department of Ophthalmology. He joined Retina Associates of Kentucky (RAK) in the summer of 2005. He has been awarded the ASRS Rhett Buckler award three times for his surgical videos and has developed/refined techniques for drainage of choroidal detachments and external needle drainage of subretinal fluid.

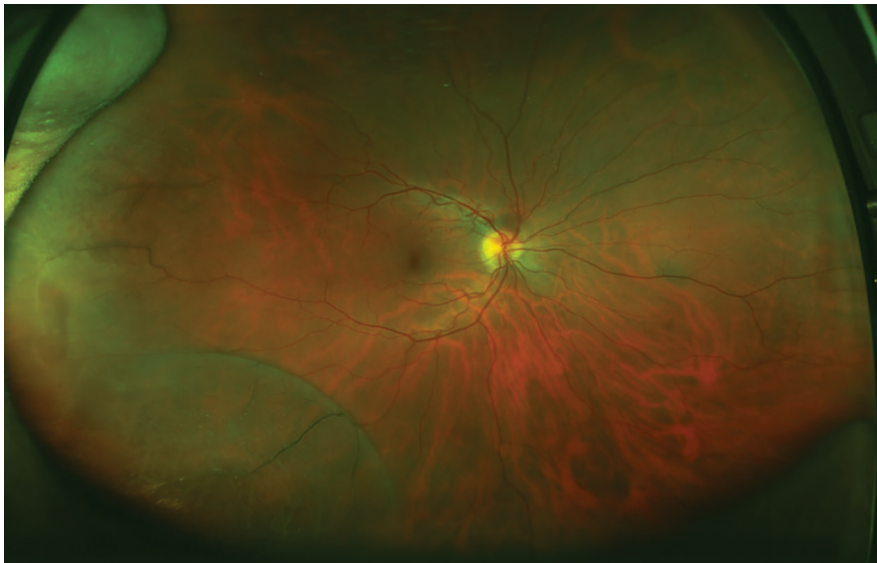

IMAGE COURTESY DR. R. SINGH

**Figure 3: Bilateral Retinoschisis**

marked areas, then monitor them over time.<sup>6</sup> UWF imaging is equally important in AMD assessment. While macular degeneration had been considered a central retinal disease, studies with UWF imaging show that up to 97% of AMD patients have peripheral pathology. As a result, researchers have suggested the disease be renamed to age-related retinal degeneration.<sup>7</sup> When managing uveitis, UWF data on vascular leakage or ischemia often changes treatment decisions.<sup>8</sup> In sickle cell disease, UWF imaging was found to detect microvascular abnormalities in the periphery that were undetected with 7SF examination.<sup>9</sup> And glaucoma specialists using color stereoscopy for ONH evaluation find UWF stereo images equivalent to manual examination.<sup>10</sup>

Optos UWF technology has even helped refine our understanding of retinal anatomy. A study by Verma et al., using UWF ICGA, found that the mean area of choroidal

circulation is 893.2 mm<sup>2</sup> (95% CI: 844.2 to 942.3 mm<sup>2</sup>).<sup>11</sup> UWF ICGA has also shown that the four vortex vein ampullae—assumed to be typical—is far short of the actual mean of eight ampullae per eye (with a range from 5 to 13).<sup>12</sup> These findings may become significant when we understand more about the impact of choroidal drainage on treatment response.

### Safer Imaging for Safer Exams and Happier Patients

**William Lahners,<sup>†</sup> MD, FACS**  
Center for Sight (Florida)

*<sup>†</sup>We are sad to report that Dr. Lahners passed away after the seminar, before he could see it in this form.*

Our anterior segment-based practice was thriving; our processes worked; customers and staff were happy. Then COVID changed everything. Like everyone else, our doctors and patients were terrified of COVID. We wanted to avoid

touching patients, especially the eyes and ocular tear film. There was pressure to reduce face-to-face time. Like every clinic, we closed waiting rooms, implemented prescreening and temperature checks. High-risk patients delayed their appointments. And we searched for additional safety protocols. Then we determined that with Optos UWF imaging devices, we could offer drop-free, arms-length consultations.

We already had the anesthetic-free tonometer, making topography and biometry more accurate for cataract surgery. Incorporating Optos UWF took this hands-off approach a step further. Additionally, UWF imaging eliminated testing redundancy for patients who had been dilated recently by their optometrist and significantly decreased patient visit time. This reduction made the practice more efficient and helped reduce the number of patients in the office at the same time.

In a typical visit, before we implemented Optos, a patient would visit three rooms—two waiting rooms and the exam room—and interact with at least four staff—two technicians, one scribe, and the

#### MODERATOR COMMENTS

We implemented a similar process, and I love the way it has engaged our technicians. Before I see a patient, the technician will say, “It looks like a nevus in one eye and floaters in the other eye.” They are not making the diagnosis, but they are looking and learning and are more excited about their role in patient care.

doctor. Now, one technician greets the patient at the door and brings them straight to the exam room, which they leave only for ancillary testing, accompanied by the same technician. The physician is notified when the patient is ready for their examination. With this new protocol in place, patient movement and staff interactions are down. In addition to decreased COVID/germ exposure, advantages include continuity of care (one tech throughout the visit), decreased patient movement (only need one or two rooms during the whole visit), and decreased dilation time. Staff and patients love the changes.

These results are not unique to our practice. One university-based study reported a reduction in eye exam visit duration of 33% (28 minutes) after implementing Optos-focused changes like ours.<sup>13</sup> A study in a private practice reported Optos implementation resulted in an additional 220 patients per year (average of 1.5 additional per day). They also noted that the incremental practice revenue from these patients allowed them to pay for the instrument in less than a year.<sup>14</sup>

When I review an **optomap**, I always hope to see nothing. As an anterior segment specialist, I obtain UWF images on 100% of my cataract and refractive surgery consults because I do not want to be ambushed by anything in the periphery. Optos is a powerful tool to document a nice, healthy eye prior to surgery. One year after implementation, our clinic flow and visit times have improved. With the addition of the high-tech **optomap**

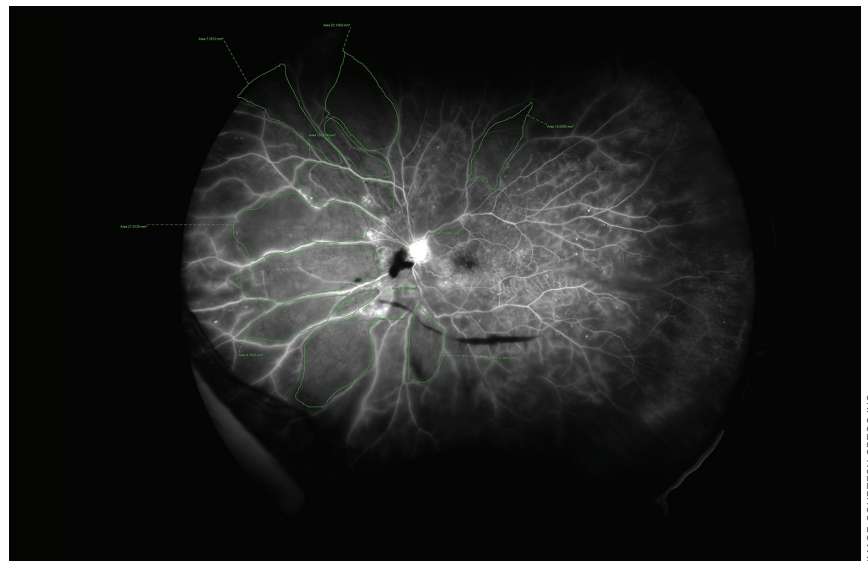


IMAGE COURTESY OPTOS INC.

**Figure 4:** Ultra-widefield FA showing the extent of retinal perfusion

imaging, we can charge more per visit, which generates more net revenue. With these changes, we have happier patients, staff, and doctors. That is a lot of happy people at Center for Sight.

## It Is Time to Reconsider Presurgical Imaging

**Carlos Martinez, MD**

*Eye Physicians of Long Beach  
(California)*

To cataract surgeons, the retina can be a strange and terrifying place. Peripheral tears, retinal detachments, and vasculitis can be challenging to see, but are critical to identify presurgically. I argued against the need for UWF until my colleague showed me a choroidal nevus that I had missed. That compelled me to explore options to improve retinal exams—which led me to **optomap**. Like many others, I discovered that the ability to quickly see, examine, and document retinal status with confidence, independent

of patient cooperation, is very satisfying and good medicine. If you are unsure whether you should add single-capture UWF imaging to your perioperative care, consider this 34-year-old myopic individual seeking LASIK. The patient was asymptomatic but had a retinal detachment.

No one wants to discover that postoperatively.

A key benefit of UWF imaging is that I can examine the whole retina quickly and with no patient discomfort. Before implementing Optos, we dilated, waited 45 minutes, then spent another 10 minutes face-to-face with the patient,

### MODERATOR COMMENTS

UWF images have improved communication from our referring doctors. Once or twice a year, I see patients with asymptomatic peripheral detachments picked up by the referring doctor. They include the Optos image with the referral, which makes everyone's job a little easier.

face-scanning the retina to ensure an exhaustive dilated exam. Now, with Optos, our patients appreciate seeing their images and spending so much less time face-to-face with an exam lens on their cornea.

Patients will also benefit from

**optomap** images. When you show a patient with DR leakage from their blood vessels, areas of ischemia, or lipid around the macula, they understand their disease far better than if you just say the words, and this deeper understanding leads

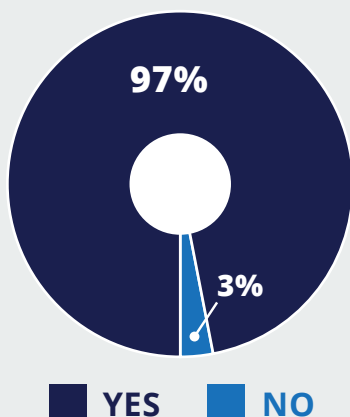
to better compliance. When an anxious patient presents with flashes and floaters, shining a bright light into their eyes for an extended examination can be traumatic. Alternately, when you show them their **optomap**, they can quickly

## UWF User Experience Poll

John W. Kitchens, MD, Retina Associates of Kentucky

During the program, the audience of approximately 300 attendees were polled regarding their experience utilizing UWF imaging. While we were pleased by the confirmation of use from some of the results—such as over 80% of the participants already owned at least one **optomap** system—others were unexpected but equally affirming of how Optos systems are changing eye care.

**Have you found unexpected pathology in a patient with no visual complaints?**

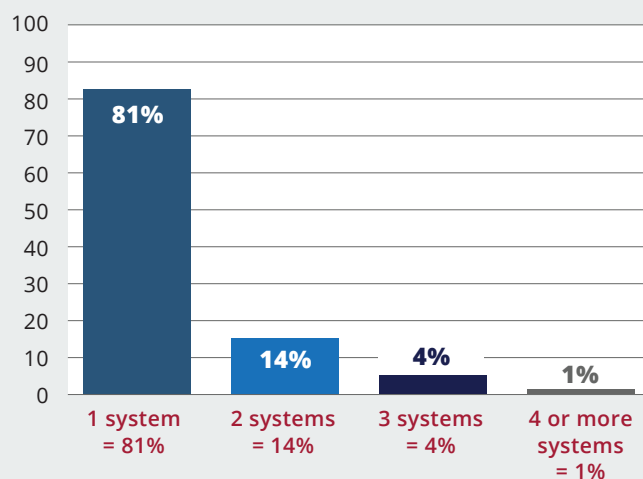


97%

of **optomap** users reported finding unexpected pathology in a patient with no visual complaints.<sup>15</sup>

*This result should not surprise me; I have had this experience myself. Yet I find it astonishing, because I cannot recall ever seeing such a compelling statistic regarding the clinical value of a diagnostic tool.*

**Number of optomap systems owned**

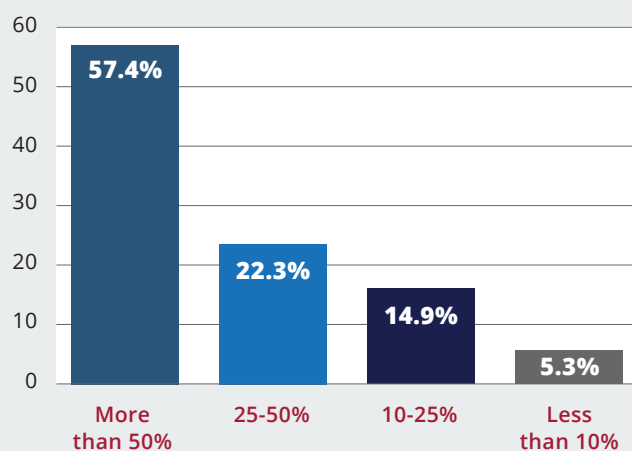


19%

report owning more than one Optos system.<sup>15</sup>

*Optos UWF is becoming a practice standard in ophthalmology.*

**Percentage of patients that receive optomap imaging**



57%

report ordering **optomap** for more than half of their patients.<sup>15</sup>

*Optomap is becoming indispensable.*

see and understand their condition, which helps them de-stress. When discussing PVD and the mechanism for retinal tears, show-and-tell makes it much easier for patients to comprehend. This type of education leaves patients with greater confidence and empowers them with a deeper understanding of their condition.

Another benefit of the **optomap** images is that they improve communication with consulting retinal doctors. Before UWF, when sending a patient to a retinal specialist, I would sometimes struggle to convey what I had seen. More than once, a patient I had referred for a tear would return, saying the specialist was unable to find the tear. Now, right in the exam room, I can share a HIPAA-compliant de-identified image to the patient's phone. When the patient arrives for their consultation, they can show the specialist exactly what I saw. There is no opportunity for miscommunication.

UWF images are also invaluable documentation for medical-legal reasons. Even with a perfectly healthy retina, complications like a PVD can occur in the weeks following surgery. In these situations, the patient always wonders if the issue was somehow caused or exacerbated by the cataract surgery. With UWF documentation, you can show the patient that there was no pathology before or immediately post-surgery. This helps them understand the PVD is unrelated to the cataract procedure and gives the patient confidence that you provided great care.

Our practice model includes a patient form that describes the test and gives four options: dilation plus **optomap**, dilation only, **optomap** only, or neither. Most patients follow our recommendation and opt for both **optomap** plus dilation. We don't use the Optos as a substitute for dilation. Some patients absolutely should be dilated—especially new patients, those with floaters and flashes, or peripheral visual field defects, and cataract consults. In glaucoma patients, dilation allows for a stereoscopic examination of the optic nerve. About 75% of our comprehensive exam patients choose to have UWF imaging. On subsequent visits, most of these patients request UWF imaging again. Patients also show their images to friends and family, which brings us new patients.

It is rare to find technology that improves practice flow, makes patients happier, and improves clinical outcomes. This technology is easy to implement and can drive incremental practice revenue. It is time for every ophthalmologist to consider single-capture UWF imaging. ●

#### REFERENCES:

- 1 Espina MP, Arcinue CA, Ma F, Camacho N, Bartsch DU, Freeman WR. Analysis of a confocal scanning laser ophthalmoscope noncontact ultra-wide field lens system in retinal and choroidal disease. *Retina*. 2015;35(12):2664-2668.
- 2 Choudhry N, Duker JS, Freund KB, et al. Classification and Guidelines for Widefield Imaging: Recommendations from the International Widefield Imaging Study Group. *Ophthalmol Retina*. 2019;3(10):843-849.
- 3 Fogliato G, Borrelli E, Iuliano L, et al. Comparison Between Ultra-Widefield Pseudocolor Imaging and Indirect Ophthalmoscopy in the Detection of Peripheral Retinal Lesions. *Ophthalmic Surg Lasers Imaging Retina*. 2019;50(9):544-549.
- 4 Lois N, Cook JA, Wang A, et al. Evaluation of a New Model of Care for People with Complications of Diabetic Retinopathy: The EMERALD Study. *Ophthalmol*. 2021;128(4):561-573.
- 5 Silva PS. Association of Predominantly Peripheral Lesions on Ultra-widefield Imaging and the Risk of Diabetic Retinopathy Worsening Over Time: Results from the DRCR Retina Network Protocol AA. Paper presented at: European Association for Diabetic Eye Complications. May 26-28; 2022; Belfast, Northern Ireland. Accessed August 22, 2022. <https://journals.sagepub.com/doi/full/10.1177/11206721221092575>
- 6 Tan CS, Chew MC, van Hemert J, Singer MA, Bell D, Sadda SR. Measuring the precise area of peripheral retinal non-perfusion using ultra-widefield imaging and its correlation with the ischaemic index. *Br J Ophthalmol*. 2016;100(2):235-239.
- 7 The Writing Committee for the OPTOS Peripheral Retina (OPERA) study, Domalpally A, Clemons TE, et al. Peripheral Retinal Changes Associated with Age-Related Macular Degeneration in the Age-Related Eye Disease Study 2. *Ophthalmol*. 2017;124(4):479-487.
- 8 Campbell JP, Leder HA, Sepah YJ, et al. Wide-field retinal imaging in the management of non-infectious posterior uveitis. *Am J Ophthalmol*. 2012;154(5):908-911.
- 9 Linz MO, Scott AW. Wide-field imaging of sickle retinopathy. *Int J Retina Vitreous*. 2019; 5(Suppl 1): 27.
- 10 Quinn NB, Azuara-Blanco A, Graham K, Hogg RE, Young IS, Kee F. Can ultra-wide field retinal imaging replace colour digital stereoscopy for glaucoma detection? *Ophthalmic Epidemiol*. 2018;25(1):63-69.
- 11 Verma A, Maram J, Alagorie AR, et al. Peripheral extent of the choroidal circulation by ultra-widefield indocyanine green angiography in healthy eyes. *Br J Ophthalmol*. 2021;105(6):824-828.
- 12 Verma A, Maram J, Alagorie AR, et al. Distribution and Location of Vortex Vein Ampullae in Healthy Human Eyes as Assessed by Ultra-Widefield Indocyanine Green Angiography. *Ophthalmol Retina*. 2020;4(5):530-534.
- 13 Lin CC, Li AS, Ma H, et al. Successful interventions to improve efficiency and reduce patient visit duration in a retina practice. *Retina*. 2021;41(10):2157-2162.
- 14 Tornambe PE. The Impact of Ultra-widefield Retinal Imaging on Practice Efficiency. *US Ophthalmic Rev*. 2017;10(1):27-30.
- 15 Dhoot D, Kitchens JW, Lahners W, Martinez C. Advances in Imaging Online Symposium, Pentavision, 2021.



